

**Skeletal and Dental Changes During Treatment of Moderate Class II Malocclusions with
Fixed Class II Correctors**

by

Austin Fairbanks

A thesis submitted in partial fulfillment of the requirements for the degree of

Master of Science

Medical Sciences - Orthodontics

University of Alberta

© Austin Fairbanks, 2024

Abstract

Introduction: The purpose of this this was to compare the skeletal and dental changes associated with the Herbst and Xbow fixed Class II correctors using Cone-Beam Computed Tomography (CBCT).

Methods: A sample of 59 Class II patients were randomly allocated into three groups. One group was treated with the Herbst appliance while another was treated with the Xbow. A control group was treated with 3M® brackets to level and align with no Class II mechanics used. All three groups had CBCT images taken before treatment and after twelve months of treatment. 3D Slicer software was used to locate skeletal and dental landmarks on the CBCT images and create 3D planes of reference to measure sagittal, anteroposterior and coronal changes of each landmark. Additionally, measurements of mandibular body length, ramus height and incisor mandibular plane angle (IMPA) were compared.

Results: Skeletally, there were no differences in mandibular body length or ramus height. There were no differences in skeletal landmarks in sagittal or axial directions. The Herbst group had anterior movement of mandibular landmarks gonion, B point and pogonion. Both Xbow and Herbst groups had anterior movement of the posterior nasal spine of the maxilla. The magnitude of the skeletal changes was almost exclusively less than 2mm so clinical significance is debateable.

Dentally, there was differences in all three directions and lower incisor proclination. Both appliances proclined mandibular incisors almost 10° as measured by IMPA. Transversely both the Herbst and Xbow, with incorporated maxillary expanders, moved the maxillary molars and

crowns laterally with crowns displacing further indicating buccal crown torque. The Xbow group had extrusion of the maxillary central incisal edge and intrusion of the mandibular central incisal edge. For dental landmarks the anteroposterior changes were the most abundant. For the Xbow group the maxillary first molar crown, maxillary central incisal edge both moved posteriorly while the mandibular central incisal edge and mandibular first molar crown and roots moved anteriorly. For the Herbst group the maxillary first molar crown moved posteriorly while the maxillary first molar root apex, mandibular central incisal edge and mandibular first molar crowns all moved anteriorly.

Conclusion: Neither the Xbow or the Herbst appliance caused increased mandibular dimensions. Minor skeletal changes in an anteroposterior direction occurred after use of the Herbst appliance. Overall, dental changes were similar for both appliances including: lower incisor proclination, lateral movement of molars due to incorporated expanders, distal tipping of maxillary molars. Additional retrusion and retroclination of maxillary incisors occurred in the Xbow group. In the Xbow group, the mandibular molars moved bodily anteriorly while the Herbst group had mesial crown tipping. Taken individually, the effect of each measurement's contribution to Class II correction is negligible, but cumulatively the effects of both the Xbow and Herbst contribute to Class II correction primarily through dental correction. With the differences between the Xbow and Herbst being so small, clinical considerations will likely serve as the key factor for orthodontists in choosing which appliance to use.

Preface

This thesis is an original work by Austin Fairbanks. Ethics approval was received for this research project from the University of Alberta's Health Research Ethics Board. Study title: "Skeletal, Functional and Dental Changes During Treatment of Mild to Moderate Class II Malocclusions With Fixed Class II Correctors: A Randomized Clinical Trial." Study ID: Pro00045191. No part of this thesis has been previously published and is the original work of Austin Fairbanks.

Acknowledgements

I would like to thank my supervisor Dr. Paul Major for his assistance and mentorship throughout this thesis. Additionally, I would like to thank Dr. Carlos Flores-Mir, Dr. Manuel Lagraverre and Dr. Giseon Heo for serving on my supervising committee. Each of you has contributed greatly to this thesis and have made it possible to achieve my goal.

My deepest gratitude is expressed to my wife Becky for her patience and steadiness as I have worked on this project. Your love was always felt, you have motivated, inspired, and cared for me in countless ways. Dean, Hugh, and Viv are lucky to have such a capable and wonderful mom.

Table of Contents

List of Tables.....	viii
List of Figures.....	ix

Chapter 1: Introduction

1.1 Introduction.....	1
1.2 Significance of the Study.....	4
1.3 Research Questions.....	5
1.4 Research Hypothesis.....	6
References.....	6

Chapter 2: Literary Review

2.1 Introduction.....	10
2.2 Class II Malocclusion.....	10
2.3 Class II Functional Appliances and Alternative Management Approaches.....	10
2.4 Treatment Effects of Class II Malocclusion	
Correctors and Craniofacial Growth Modification.....	12
2.5 Review of Herbst Appliance.....	13
2.6 Review of Xbow Appliance.....	14
2.7 Review of Lateral Cephalograms.....	16
2.8 Review of CBCT.....	16
2.9 Review of CBCT Landmarking and Measurement Techniques.....	18
2.10 Summary.....	19
References.....	20

Chapter 3: Skeletal and Dental Changes During Treatment of Moderate Class II Malocclusions with Fixed Class II Correctors: A Randomized Controlled Trial

3.1 Introduction.....	26
3.2 Methods.....	28
3.3 Statistical Analysis.....	42
3.4 Results.....	45

3.5 Discussion.....	55
3.6 Limitations.....	61
3.7 Conclusions.....	61
References.....	62

Chapter 4: Final Discussion

4.1 General Discussion and Summary of Findings.....	67
4.2 Study Limitations.....	67
4.3 Future Recommendations.....	69

Bibliography.....	70
--------------------------	-----------

Appendix.....	83
----------------------	-----------

List of Tables

Table 1. Intra-class Correlation Coefficient (ICC) Guidelines.....	42
Table 2. Average Paired Landmark List.....	44
Table 3. Descriptive Statistics of the Sample.....	45
Table 4. Bonferroni Post Hoc Test for Skeletal Landmarks Anteroposterior Direction.....	48
Table 5. Bonferroni Post Hoc Test for Dental Landmarks Sagittal Direction.....	50
Table 6. Bonferroni Post Hoc Test for Dental Landmarks Anteroposterior Direction.....	52
Table 7. Bonferroni Post Hoc Test for Dental Landmarks Axial Direction.....	53
Table 8. Bonferroni Post Hoc Test for Mandibular Body Length, Ramus Height, IMPA.....	55
Table 9. Overall ANB Angle, Molar Relationship and Overjet Change.....	55
Table 10. Assumption Testing for One-Way MANOVA at T1.....	83
Table 11. Assumption Testing for One-Way MANOVA for T2-T1.....	84
Table 12. MANOVA at T1 Comparing Treatment Groups.....	95
Table 13. Box's Test of Equality of Covariance Matrices T1.....	96
Table 14. MANOVA of T2-T1 Comparing Treatment Groups.....	104
Table 15. Box's Test of Equality of Covariance Matrices T2-T1.....	104
Table 16. Assumption Testing for One-Way Repeated Measures ANOVA.....	106
Table 17. Mauchly's Test of Sphericity One-Way Repeated Measures ANOVA.....	110
Table 18. p-Values of Interaction Term from One-Way Repeated Measures ANOVA.....	111
Table 19. p-Values of Appliance Term from One-Way Repeated Measures ANOVA.....	111
Table 20. p-Values of Landmark Term from One-Way Repeated Measures ANOVA.....	112
Table 21. Box's Test of Equality of Covariance Matrices One-Way Repeated ANOVA.....	116
Table 22. Sample Sizes of Groups.....	128
Table 23. Intraclass Correlation Coefficient for CBCT Landmarks.....	129
Table 24. Intraclass Correlation Coefficient for Lateral Cephalogram Landmarks.....	131
Table 25. Labels of Each Landmark.....	132

List of Figures

Figure 1. Orientation of CBCT Scans. Front, Right and Top Views.....	32
Figure 2. Descriptions of Skeletal and Dental CBCT Landmarks.....	33
Figure 3. Landmarks Used to Create 3D Reference Planes.....	40
Figure 4. Boxplots for MANOVA at T1.....	85
Figure 5. Scatter Matrix for MANOVA at T1 and Selected Examples.....	96
Figure 6. Boxplots for MANOVA T2-T1.....	97
Figure 7. Scatter Matrix for MANOVA for T2-T1 and Selected Examples.....	105
Figure 8. Boxplots for One-Way Repeated Measures ANOVA Skeletal Sagittal.....	109
Figure 9. Profile Plots Indicating Landmark Directional Changes T2-T1.....	113
Figure 10. Scatter Matrix Skeletal Sagittal.....	117
Figure 11. Boxplots for One-Way Repeated Measures ANOVA Skeletal Anteroposterior.....	117
Figure 12. Scatter Matrix Skeletal Anteroposterior.....	119
Figure 13. Boxplots for One-Way Repeated Measures ANOVA Skeletal Axial.....	119
Figure 14. Scatter Matrix Skeletal Axial.....	121
Figure 15. Boxplots for One-Way Repeated Measures ANOVA Dental Sagittal.....	121
Figure 16. Scatter Matrix Dental Sagittal.....	123
Figure 17. Boxplots for One-Way Repeated Measures ANOVA Dental Anteroposterior.....	123
Figure 18. Scatter Matrix Dental Anteroposterior.....	125
Figure 19. Boxplots for One-Way Repeated Measures ANOVA Dental Axial.....	125
Figure 20. Scatter Matrix Dental Axial.....	127
Figure 21. Boxplots for One-Way Repeated Measures ANOVA Mandible Dimensions and IMPA.....	127
Figure 22. Scatter Matrix Mandible Dimensions and IMPA.....	128

Chapter 1: Introduction

1.1 Introduction

Edward H. Angle is considered the “father of modern orthodontics” (1). According to his classification, a Class II malocclusion occurs when the lower molar is positioned distally relative to the upper molar rather than the ideal occlusal relationship (the mesiobuccal cusp of the first maxillary molar occluding in the buccal groove of the first mandibular molar) (1). Class II malocclusions occur when there is a discrepancy between the upper and lower jaws or dentition, resulting in an improper relationship between the arches.

The etiology of Class II malocclusions can be skeletal, dental, or a combination of both. Contributing skeletal factors can include either an oversized or protruded maxilla, an undersized or retruded mandible, or a combination of these features. Most commonly, a retruded mandible is the cause of a Class II occlusion (2). The prevalence of malocclusions varies with ethnicity. Those of Caucasian and Northern European descent have the highest prevalence of Class II at 25%, compared to the general American population of 15% (1). Some notable dental etiologies of Class II malocclusions include missing or crowded teeth, premature loss of primary dentition, tooth-size arch length discrepancies, and oral habits. An accurate diagnosis of the cause of the malocclusion is essential to appropriate orthodontic management.

Treating a malocclusion is imperative to achieve a functional and esthetic result. Esthetic issues are the most prevalent factor in patients seeking treatment (3). Malocclusions can significantly negatively impact a patient’s self-esteem and psychosocial well-being; it can be detrimental as a social handicap (1), (3). In addition to appearance, orthodontists must consider patients’ oral function and risks of trauma, periodontal disease, or tooth decay (1). Ideally, orthodontic treatment aims to achieve an esthetic result with a harmonious occlusion from both a dental and facial standpoint.

Treatment options, depending on the severity of the malocclusion, can be treated surgically or non-surgically. A surgical treatment plan is recommended when the patient’s orthodontic issues are severe enough that less invasive treatment options do not offer an

acceptable alternative (4). Surgical treatment options include a single or double jaw surgery, often in conjunction with additional procedures such as a chin augmentation (4). Although orthognathic surgery and comprehensive orthodontic treatment will address and correct severe conditions, this invasive option introduces several challenges for the patient: surgical risks, financial burden, and extended treatment and recovery time.

A non-surgical approach is termed as a ‘camouflage’ option. In a camouflage case, treatment aims to achieve a reasonable occlusion despite the underlying skeletal issue. The patient must have a satisfactory facial balance or accept his facial imbalances as a non-surgical route will not significantly affect overall facial appearance. Camouflaging a Class II malocclusion jaw relationship involves retracting the maxillary incisors and increasing the inclination of the mandibular incisors (5). Extraction of teeth, typically premolars, may be included in treatment; this has been a widely debated topic over the history of orthodontics (6). There is limited evidence of premolar extractions having either an overall negative or positive effect on treatment outcomes when compared to a non-extraction treatment (7). In growing patients, orthodontists have utilized growth modification as a non-surgical attempt to achieve Class II malocclusion correction partly through increased growth or forward repositioning of the mandible or reduced forward growth of the maxilla. As most orthodontic patients are pubescent, orthodontists attempt to capitalize on their concurrent craniofacial growth to obtain some degree of skeletal changes without invasive surgeries. Miniscrew implants have increased the potential of non-surgical camouflage and made it possible for more cases to be treated non-surgically (8).

Applying force and displacing a craniofacial skeletal structure will likely encourage new growth in the area where the force is applied. In Class II malocclusion patients, a so-called “functional appliance” is used to change the posture of the mandible into a downward and forward direction (9). The condyle displacement away from the articular eminence stimulates the condylar cartilage's growth, causing the mandible's overall length to increase (10). Several types of functional appliances can achieve this effect, and they can be removable or fixed. Removable functional appliances to treat a Class II malocclusion include Twin-Block, Frankel-II, and Bionator. These appliances rely heavily on patient compliance, while fixed functional appliances do not, as they are cemented temporarily for the course of treatment. Fixed functional appliances,

more specifically, the Herbst and Xbow (pronounced crossbow) appliances, will be studied in this project.

The Xbow is a patented design and is a trademark of Dr. Duncan W. Higgins (11). It consists of a maxillary expansion appliance and a mandibular holding arch called a Triple “L” Arch (lower labial lingual arch) (11). Both components are banded on the first molars, including occlusal rests on the first bicuspid and maxillary second molars (12). The holding arches are connected bilaterally by Forsus Fatigue Resistant Devices. L pins are inserted into the maxillary first molar band tubes and cinched to the labial aspect of the mandibular arch(11). A Gurin lock slides and locks into place on the buccal arch of the mandible to adjust the Class II activation(12). The Xbow is a relatively new fixed class II corrector; the initial research article was published in 2009 (13). Multiple studies have since been released (14), (15), (16), (17), (18), (13), (19), (20), (21), (22).

The Herbst appliance has a much longer history than the Xbow. It was first introduced by Emil Herbst in 1905 and reintroduced to the orthodontic community by Pancherz in 1979 (23), (24). To this day, it remains a popular fixed Class II malocclusion corrector. Extensive research continues regarding this appliance. There are many variations of Herbst appliances, generally categorized into four basic designs: banded, cast splint, stainless steel crown, and acrylic splint (25). The maxillary and mandibular components are connected via a telescoping mechanism, utilizing a tube and plunger with locking screws at both ends of the mechanism (25). The maxillary pivot is soldered to the maxillary first molar, while the mandibular pivot is located near the mandibular first premolar (25). Like Xbow, Herbst designs can include a palatal expander in the maxilla. In this study, we used the stainless-steel crown Herbst design.

Traditionally, 2D radiographs (lateral cephalograms in particular) have been used to determine changes in anatomical landmark locations before, during, and after treatment. Broadbent first introduced cephalometrics in 1931, and it is standard practice in current orthodontic treatment planning (26). Landmarking anatomic structures in this way can be difficult. Lateral cephalograms have been described as a two-dimensional shadow of a three-dimensional object (27). Landmarking errors include both projection errors and misidentification

(27). Because X-rays originate from a very small source and are non-parallel, 2D radiographs display distorted enlargements, with each point having a different enlargement factor (27). Landmark identification errors each have a different severity, depending on the individual landmark and the amount of superimposition (27). Alternatively, cone-beam computed tomography has been introduced as a method to overcome some of the inaccuracies of lateral cephalograms (28).

Cone-beam computed tomography (CBCT) was first introduced to the dental field in 1999 (29). It was developed to provide high-resolution images at a much lower radiation dose than conventional computed tomography (29). As a result, complex anatomic relationships and surrounding structures can be visualized undistorted in all three dimensions (28). CBCT, unlike lateral cephalometric radiography, can give information on transverse or unilateral aspects of malocclusions or craniofacial anomalies (30). This imaging has many orthodontic applications: assessing the position of unerupted teeth, identifying resorption of teeth, cleft palate assessment, and analyzing bone dimensions before placing mini-screws, to name a few (31). In 2013, the American Academy of Oral and Maxillofacial Radiology released a position statement and guidelines for using CBCT in orthodontics (28). This statement has been updated in 2024 to follow the most recent evidence-based recommendation (32). These guidelines stress the importance of the ALARA principle (as low as reasonably achievable) to reduce the dose of ionizing radiation to patients (28). CBCT has been used to research skeletal and dental changes after the use of Herbst appliances (33), (34), (35), (36). Only one study has been published using CBCT to investigate skeletal and dental changes produced by the Xbow (15). The primary focus of this article was upper airway dimensions, with skeletal and dental effects only measured off two-dimensional lateral cephalogram and panoramic radiographs derived from the CBCT, not directly from the three-dimensional CBCT image (15).

1.2 Significance of the Study

With a relatively high prevalence of orthodontic patients having Class II malocclusions, proper treatment is integral for ideal patient outcomes. Discussion regarding the efficacy of growth modification is ongoing, with no clear consensus in the orthodontic community. It is critical that we understand how fixed functional appliances affect growing patients. Is Class II

malocclusion correction achieved only by skeletal or dental changes? Is the correction a combination of both? And if so, what proportion of that correction is skeletal? This study will address these questions for both the Xbow and the Herbst appliances. Comparatively, the Xbow has fewer published studies as it is a much newer appliance. Further insight regarding the efficacy of the Xbow can contribute to an orthodontist's decision regarding which fixed Class II malocclusion corrector to utilize. It is important to note that the Herbst and Xbow appliances have been compared directly to each other in an article published in 2021 (this will be referred to as the 2021 article or study throughout the remainder of this paper). This 2021 article investigated the skeletal and dental effects of both appliances (19), which naturally leads to this question: How does this study differ from what was studied in 2021? The answer lies in the methodology.

High-quality, randomized, controlled trials are integral to evidence-based medicine (37); they form the backbone of systematic reviews, which should be at the forefront of evidence-based decision-making (37). Without high-quality studies included in systematic reviews; the conclusions drawn from these systematic reviews are not always beneficial to evidence-based treatment decisions (7). A guest editorial in the American Journal of Orthodontics and Dentofacial Orthopedics concluded that further evidence is required through well-designed randomized clinical trials (38). This study is a randomized clinical trial, unlike the 2021 publication, which utilized a retrospective design. This study includes a concurrent control group, a single clinician treating all patient groups, and 3D landmarking with CBCT acquisition; this will help to differentiate and strengthen the results compared to the 2021 article.

1.3 Research Questions

1. Does treatment with Herbst or the Xbow cause skeletal changes compared to normally growing patients?
 - a. If there is increased mandibular size does the mandible increase in body length, ramus height or both?
2. Does treatment with Herbst or the Xbow cause dental changes compared to normally growing patients?

1.4 Research Hypothesis

1. Treatment with the Herbst or Xbow appliances does not cause skeletal changes compared to normally growing patients.
 - a. Herbst and Xbow treatment do not cause increased mandibular size.
2. Treatment with the Herbst or Xbow appliances does not cause dental changes compared to normally growing patients.

References

1. Proffit WR, Fields HW, Larson BE, Sarver DM. Contemporary orthodontics. 6th ed. Philadelphia, PA: Elsevier; 2019. 2–10 p.
2. McNamara J. Components of class II malocclusion in children 8-10 years of age. *Angle Orthodontist*. 1981;51(3):177–202.
3. Lin F, Ren M, Yao L, He Y, Guo J, Ye Wenzhou Q. Psychosocial impact of dental esthetics regulates motivation to seek orthodontic treatment. *American Journal of Orthodontics and Dentofacial Orthopedics*. 2016;150(3):476-82.
4. Proffit WR, Fields HW, Larson BE, Sarver DM. Contemporary Orthodontics. 6th ed. Philadelphia, PA: Elsevier; 2019. 657–678 p.
5. Proffit WR, Fields HW, Larson BE, Sarver DM. Contemporary Orthodontics. 6th ed. Philadelphia, PA: Elsevier; 2019. 225–226 p.
6. Case CS. The question of extraction in orthodontia. *American Journal of Orthodontics and Dentofacial Orthopedics*. 1964;50(9):660–91.
7. Benson PE, Alshawy E, Fenton GD, Frawley T, Misra S, Ng T, O'Malley P, Smith G. Extraction vs nonextraction of premolars for orthodontic treatment: A scoping review examining the extent, range, and characteristics of the literature. *American Journal of Orthodontics and Dentofacial Orthopedics*. 2023;164(3):368–76.
8. Paik CH, Park IK, Woo YJ, Kim TW. Orthodontic Miniscrew Implant. Harradine N, editor. Mosby Ltd; 2009.
9. Proffit WR, Fields HW, Larson BE, Sarver DM. Contemporary Orthodontics. 6th ed. Philadelphia, PA: Elsevier; 2019. 455–459 p.
10. Baccetti T, Franchi L, Toth LR, McNamara JA. Treatment timing for Twin-block therapy. *American Journal of Orthodontics and Dentofacial Orthopedics*. 2000;118(2):159–70.

11. Great Lakes Dental Technologies [Internet]. Tonawanda, NY: [publisher unknown]; 2024. Higgins XBOW Class II Corrector. [cited 2024 Jan 14]. Available from: <https://www.greatlakesdentaltech.com/higgins-xbow-class-ii-corrector.html>
12. Xbow® [Internet]. [place unknown]: Crossbow® Orthodontic; 2024. About the Xbow® (Crossbow®) Class II Corrector. [cited 2023 Oct 23]. Available from: <https://crossboworthodontic.com/xbow-class-ii-corrector/>
13. Flores-Mir C, Barnett G, Higgins DW, Heo G, Major PW. Short-term skeletal and dental effects of the Xbow appliance as measured on lateral cephalograms. *American Journal of Orthodontics and Dentofacial Orthopedics*. 2009;136(6):822–32.
14. Flores-Mir C, Witt MM, Heo G, Major PW. Analysis of anterior dentoalveolar and perioral aesthetic characteristics and their impact on the decision to undergo a Phase II orthodontic treatment. *European Journal of Orthodontics*. 2014;36:719-26.
15. Erbas B, Kocadereli I. Upper airway changes after Xbow appliance therapy evaluated with cone beam computed tomography. *Angle Orthodontist*. 2014;84(4):693–700.
16. Aziz T, Nassar U, Flores-Mir C. Prediction of lower incisor proclination during Xbow treatment based on initial cephalometric variables. *Angle Orthodontist*. 2011;0(0):1-8.
17. Miller RA, Tieu L, Flores-Mir C. Incisor inclination changes produced by two compliance-free Class II correction protocols for the treatment of mild to moderate Class II malocclusions. *Angle Orthodontist*. 2013;83(3):431–6.
18. Flores-Mir C, Young A, Greiss A, Woynorowski M, Peng J. Lower incisor inclination changes during Xbow treatment according to vertical facial type. *Angle Orthodontist*. 2010 Nov;80(6):1075–80.
19. Insabralde NM, Rodrigues de Almeida M, Rodrigues de Almeida-Pedrin R, Flores-Mir C, Castanha Henriques JF. Retrospective comparison of dental and skeletal effects in the treatment of Class II malocclusion between Herbst and Xbow appliances. *American Journal of Orthodontics and Dentofacial Orthopedics*. 2021;160(4):544–51.
20. Tieu L, Normando D, Toogood R, Flores-Mir C. External apical root resorption generated by Forsus simultaneously with brackets vs. Xbow followed by brackets to correct Class II malocclusions. *Journal of the World Federation of Orthodontists*. 2015;4:120–3.
21. Flores-Mir C, McGrath L, Heo G, Major PW. Efficiency of molar distalization associated with second and third molar eruption stage: A systematic review. *Angle Orthodontist*. 2013;83(4):735-42.

22. Ehsani S, Nebbe B, Normando D, Lagravere MO, Flores-Mir C. Dental and skeletal changes in mild to moderate Class II malocclusions treated by either a Twin-block or Xbow appliance followed by full fixed orthodontic treatment. *Angle Orthodontist*. 2015;85(6):997–1002.
23. Pancherz H. The Herbst appliance - Its biologic effects and clinical use. *American Journal of Orthodontics*. 1985;87(1):1-20.
24. Windmiller EC, Harrisburg M. The acrylic-splint Herbst appliance: A cephalometric evaluation. *American Journal of Orthodontics and Dentofacial Orthopedics*. 1993;104(1):73–84.
25. Paulsen HU. Orthodontic Treatment of the Class II Noncompliant patient. Papadopoulos MA, editor. Mosby; 2006. p. 35–7.
26. Broadbent BH. A new X-ray technique and its application to orthodontia. *Angle Orthodontist*. 1931;1(2):45–66.
27. Baumrind S, Frantz RC. The reliability of head film measurements 1. Landmark identification. *American Journal of Orthodontics*. 1971;60(2):111–27.
28. Scarfe WC. Clinical recommendations regarding use of cone beam computed tomography in orthodontics. Position statement by the American Academy of Oral and Maxillofacial Radiology. *Oral Surg Oral Med Oral Pathol Oral Radiol*. 2013;116(2):238–57.
29. Arai Y, Tammisalo E, Iwai K, Hashimoto K, Shinoda K. Development of a compact computed tomographic apparatus for dental use. *Dentomaxillofacial Radiology*. 1999;28:245–8.
30. Scarfe WC, Azevedo B, Toghyani S, Farman AG. Cone Beam Computed Tomographic imaging in orthodontics. *Australian Dental Journal*. 2017;62(1):33–50.
31. Shukla S, Chug A, Afrashtehfar KI. Role of cone beam computed tomography in diagnosis and treatment planning in dentistry: An update. *Journal of International Society of Preventive and Community Dentistry*. 2017;7:125–36.
32. Benavides E, Krecioch JR, Connolly RT, Allareddy T, Buchanan A, Spelic D, O’Brien KK, Keels MA, Mascarenhas AK, Duong M, Aerne-Bowe MJ, Ziegler KM, Lipman RD. Optimizing radiation safety in dentistry Clinical recommendations and regulatory considerations. *The Journal of the American Dental Association*. 2024;155(4):280-293.
33. Sangalli KL, Dutra-Horstmann KL, Correr GM, Topolski F, Flores-Mir C, Lagravère MO, Moro A. Three-dimensional skeletal and dentoalveolar sagittal and vertical changes associated with cantilever Herbst appliance in prepubertal patients with Class II malocclusion. *American Journal of Orthodontics and Dentofacial Orthopedics*. 2022;161(5):638-651.

34. Fan Y, Schneider P, Matthews H, Roberts WE, Xu T, Wei R, Claes P, Clement J, Kilpatrick N, Penington A. 3D assessment of mandibular skeletal effects produced by the Herbst appliance. *BMC Oral Health*. 2020;20:2-9.
35. Cheib PL, Cevidanes LHS, Ruellas AC de O, Franchi L, Braga WFM, Oliveira D, Souki BQ. Displacement of the mandibular condyles immediately after Herbst appliance insertion - 3D assessment. *Turkish Journal of Orthodontics*. 2016;29(2):31–7.
36. Lecornu M, Cevidanes LHS, Zhu H, Wu C Da, Larson B, Nguyen T. Three-dimensional treatment outcomes in Class II patients treated with the Herbst appliance: A pilot study. *American Journal of Orthodontics and Dentofacial Orthopedics*. 2013;144(6):818–30.
37. Pandis N, Fleming PS, Hopewell S, Altman DG. The CONSORT Statement: Application within and adaptations for orthodontic trials. *American Journal of Orthodontics and Dentofacial Orthopedics*. 2015;147(6):663–79.
38. Millett DT, Benson PE, Cunningham SJ, McIntyre GT, Fleming PS, Naini FB, Tsihlaki A. Systematic reviews in orthodontics: A fresh look to promote renewal and reduce redundancy. *American Journal of Orthodontics and Dentofacial Orthopedics*. 2022;162:1–2.

Chapter 2: Literature Review

2.1 Introduction

This literature review will provide the necessary background information pertinent to Class II correction of malocclusions in orthodontic patients. Beginning with a definition of Class II malocclusion, different treatment approaches are discussed, in particular, the Herbst and Xbow fixed functional appliances. The positive and negative attributes of two forms of dental radiography, lateral cephalogram and cone-beam computed tomography, are evaluated and their current roles in orthodontic research.

2.2 Class II Malocclusion

Class II malocclusions can originate from dental or skeletal elements but often exist simultaneously (1). EH Angle classified a malocclusion as a Class II malocclusion when the mandibular molars are positioned distally relative to the maxillary molars (2). Further, there are two divisions of Class II malocclusions based on the inclination of the maxillary central incisors. Class II Division 1 malocclusions have labially inclined maxillary incisors with increased overjet (1); Class II Division 2 malocclusions have lingual inclination of maxillary central incisors that are overlapped labially by the maxillary laterals (1). Nearly one-third of the American population has a Class II malocclusion (3). The correction of Class II malocclusions constitutes almost half of the treatment protocols in North American orthodontic practices (3). Although the sagittal origin is the most important discriminating factor for a Class II malocclusion, vertical and transversal components also interact. An anteroposterior skeletal discrepancy is often due to mandibular retrusion; however, the maxilla can also be protrusive (1). Excessive vertical development, particularly in anterior face height, can be a significant factor (4). Transverse maxillary discrepancy is also common among these patients (3).

2.3 Class II Functional Appliances and Alternative Management Approaches

A functional appliance for Class II malocclusion correction changes the posture of the mandible, causing the patient to hold it open and/or forward (2). Functional appliances are categorized as removable or fixed appliances.

Removable functional appliances were introduced in the 1920s with the Activator, which became widely accepted (2). In 1964, the Bionator, which used flanges to position the mandible more anteriorly, was proposed (5). The Frankel appliance, or functional regulator, came later. It uses plastic buccal shields and lip pads to hold soft tissues away from the teeth, disrupting the tongue-lip/cheek equilibrium (2). The Twin Block was presented in 1977 and utilizes upper and lower bite-blocks that interlock at a 45° angle to induce a functional mandibular displacement (5), (6). Patient adherence is critical for successful treatment with removable appliances.

Fixed functional appliances are attractive to clinicians since they require less patient cooperation (they are cemented and need just proper maintenance). The Herbst appliance originated in the early 1900s, and it is the most popular fixed functional appliance alternative. It is thoroughly discussed in section 2.4 (2). The mandibular anterior repositioning appliance, also known as MARA, was developed in the 1990s as a more durable and streamlined alternative to the Herbst (2). The MARA requires the patient to advance their mandible to close fully; advancement is increased by adding shims (2). The Jasper Jumper has flexible intraoral force modules to aid in Class II correction (7). Forsus™ springs are inserted intraorally into the headgear tube and onto heavy archwires. Shims added to Forsus™ springs increase mandibular advancement (2). The Xbow is a newer fixed Class II corrector, that uses the Forsus™ springs, discussed further in section 2.5.

Functional appliances are just one of several modalities to address Class II malocclusions. The Carrière® Motion 3D™ appliance was developed in 2004 (CMA; Henry Schein Orthodontics, Carlsbad, Calif). It consists of two rigid bars bonded bilaterally to the maxillary canines and first molars (8). Additionally, the Carrière® appliance involves a removable Essix-type retainer worn on the mandible with intermaxillary elastics worn by the patient (8). This appliance does not strictly fit in either the fixed or removable category. Another appliance that utilizes interarch elastics is the Wilson® 3D® bimetric maxillary distalizing arch (RMO®, Franklin, IN) (9). It helps to establish a Class I molar relationship primarily through distalization of the maxillary molars (9). The Distal Jet (American Orthodontics, Sheboygan, Wisc.) was developed by Carano and Testa in 1996 with the goal of maxillary molar distalization without requiring compliance from the patient regarding elastic wear (10). Additionally,

headgears can be used to restrain the growth of the maxilla via extraoral forces, allowing the mandible to grow in mandibular deficient patients (2). Finally, Class II interarch elastics, worn from mandibular molars to maxillary incisors, are used particularly in mild Class II malocclusion cases.

2.4 Treatment Effects of Class II Malocclusion Correctors and Craniofacial Growth Modification

The most consistent diagnostic finding in Class II malocclusion patients is mandibular retrusion. Functional appliances stimulate mandibular growth by the forward posturing of the mandible to correct an occlusal disharmony (11). The influence on mandibular growth is controversial with some studies supporting increased mandibular growth, while others state no additional growth of the mandible is noted. There is evidence of mandibular advancement relative to the cranial base and increased mandibular length when using functional appliances (12). A systematic review reported that two-thirds of the identified studies showed clinically significant elongation (over 2mm increase) of total mandibular length after treatment with functional appliances (11). Mandibular length increases are more significant when treatment occurs during pubertal peak in skeletal maturation (11). On the other hand, published literature claim that fixed functional appliances do not produce a significant positional or dimensional skeletal effect on the mandible (13). Additionally, no significant long-term dentoskeletal changes are observed when comparing patients treated with functional appliances to matched control groups (14). More methodologically sound clinical trials are required to provide higher-quality evidence to demonstrate the effect of fixed functional appliances on mandibular growth (13).

Dental changes can help to camouflage a skeletal Class II malocclusion pattern during craniofacial growth modification. It has been reported that 23% to 80% of Class II malocclusion corrections from functional appliances are due to dental changes (7). Functional appliances, considered as a group, significantly decrease the overjet (12); they cause proclination of the lower incisors and retroclination of the upper incisors (12). Two systematic reviews have concluded that there is no relevant clinically important association between the degree of mandibular incisor proclination and increased gingival recession (15).

Patient selection is a key factor in predicting outcomes of growth modification. Patients that have a normal growth direction or are horizontal growers, with mandibular angles (Co-Go-Me angle less than 125.5°), generally have better response than vertical growers (16). This is likely due to the vertical component of the remaining craniofacial growth. Predictions are difficult since there is considerable variation in patient's craniofacial growth, both with and without treatment (17).

2.5 Review of Herbst Appliance

The Herbst appliance, introduced in 1905 by Emil Herbst, was popularized in 1979 by Pancherz (18), (19). Fixed functional appliances, Herbst included, are commonly used in the United States and mainland Europe (20). There are multiple designs for Herbst appliances including banded, cast splint, stainless-steel crown, and acrylic splints (21). Unless explicitly stated, we will refer to the stainless-steel crown design during this discussion. Stainless-steel crowns cement onto the first molars, and a transpalatal arch or rapid maxillary expander is bonded on the upper dentition (20). In the mandible, a lingual holding arch includes a cantilever extending from the buccal of the first molar crown to the first premolar area (20), (21). The maxillary and mandibular components connect via a telescoping mechanism with locking screws. The appliance advances the mandible and is incrementally activated using crimpable shims (20). Herbst appliances do not rely on patient adherence, but often suffer from partial breakage (2).

The Herbst appliance is categorized as a passive tooth-borne functional appliance (2). It is qualified as passive because of its dependence on soft tissue stretch and muscular activity to produce treatment effects, not an intrinsic force-generating capacity of the telescoping mechanism (2). The jaw is repositioned anteriorly and downward, displacing the condyles away from the glenoid fossa (22). When patients close, the mandible is continuously positioned forward and down (22).

Treatment times for Herbst appliances range from 8-12 months with the goal of overcorrection to account for 1-2mm of relapse (2). During treatment, brackets can be bonded on incisors and canines along with maxillary premolars to allow alignment and provide stabilization of lower incisors (2). Determining which appliance design to use (acrylic splint vs. crown

Herbst) is a clinical management decision as the skeletal and dental differences are not clinically significant (23).

The Herbst appliance does not produce significant skeletal changes consistent with other Class II malocclusion correctors. In the maxilla, there is minimal effect and notably does not show a “headgear effect” (24). Compared to untreated control patients (mean ages 9 yr 8 months and 11 yr 2 months) , Herbst patients (mean age 9 yr 10 months and 12 yr 1 month) had increased mandibular body length in the 2-3mm range (23), (25), (26). Pancherz reported increased mandibular body lengths of 2.2mm, while Windmiller reported 3.4mm (27) (26) (19).

Class II malocclusion correction with a Herbst is primarily through dentoalveolar effects (24). Maxillary first molars move distally (1.4-2.8mm) and intrude (0.4-1.0mm) (26), (25), (22). Mandibular first molars move anteriorly (1.0mm) and extrude (0.7-1.3mm) (25), (26) (22). Maxillary incisors retrocline (3.8-5.7°) and move posteriorly (1.4-1.5mm), while mandibular incisors are proclined (4-6.6°), moving anteriorly (1.0-1.8mm) (25), (26), (22). Pancherz advocated for a treatment protocol of overcorrection until the incisors were in an edge-to-edge relationship to account for relapse (26).

2.6 Review of Xbow Appliance

The Xbow, was patented by Dr. Duncan W. Higgins in 2001, and is used in late mixed or early permanent dentition as a Phase 1 appliance (28), (29). The three components of Xbows include a maxillary Hyrax expander, mandibular labial and lingual bow, and Forsus® fatigue-resistant device springs (29). The maxillary expander is anchored to the dentition using bands (with included headgear tubes) cemented to the first molars and either bands or occlusal rests on the first premolars and, if erupted, the second molars (29), (30), (31). The mandibular component, called a Triple “L” Arch (lower labial lingual), is banded onto the first molars with occlusal rests on the first premolars (30), (29). Both the labial and lingual bows of the Triple “L” Arch are in passive contact with the mandibular incisors. The labial bow uses 3M™ Unitek™ Gurin locks, allowing the Forsus® springs to reactivate (29). Forsus® springs attach to the maxillary expander using L pins through the headgear tubes, and cinches onto the mandibular

labial bow near the canine or first premolar region posterior to the Gurin lock (30). When fully compressed, the spring force is approximately two hundred grams (15).

The Xbow is categorized as a non-protrusive inter-arch Class II malocclusion corrector (29). Since Forsus springs do not rigidly hold the mandible forward, the patient can function in centric occlusion (29). In other words, patients can posteriorly reposition their mandible using a Xbow appliance so the condyle is not always displaced out of the glenoid fossa.

During Xbow treatment braces can be bonded on the front four teeth what is typically referred to as a 2x4 arrangement (29). The main reason for 2x4 use during Xbow treatment is to decompensate maxillary incisors to increase the available overjet for Class II correction (15). The proposed Xbow treatment protocol includes overcorrecting to a Class III molar relationship with maxillary first premolars in an end-to-end relationship with the mandibular second premolars. This accounts for relapse following appliance removal (29). Xbow treatment has short treatment times for Class II correction of mild/moderate malocclusions with a mean of 4.5 months (29). Compared to using Forsus springs on edgewise appliances, Xbow treatment time is six months shorter (15). Comparing Xbow and Twin-block appliances, the overall treatment time (which included phase II full bonding following phase 1) was not different (32).

Overall, the Xbow accomplishes Class II malocclusion correction with more dental than skeletal changes, although some skeletal effects have been shown in the literature. Minor increases in skeletal vertical dimension have been reported, while a more recent study found no significant vertical changes (29), (22). Xbow treatment has a “headgear effect” by restricting maxillary skeletal anterior movement and displacing the upper molars posteriorly (29). Skeletal reduction in overjet caused by Xbow treatment is limited, accounting for only 15% overall and only 0.47mm (29). Xbow treatment reduces the ANB angle with most of the change from the maxillary, not mandibular measurements (29).

Most Class II malocclusion corrections with Xbow treatment are due to dental changes. In an initial study, the Xbow reduced overjet by a total of 3mm, primarily caused by dental movements (29). Sixty percent of the overjet reduction was due to equal amounts of maxillary

incisors moving posteriorly while mandibular incisors moved anteriorly (29). Xbow treatment results in a small amount of anterior movement of mandibular first molars and a greater amount of posterior movement of maxillary first molars (29). No difference was found between the maxillary first molar distalization amount, depending on whether the maxillary second molars erupted (33). Consistent with other Class II malocclusion correctors, lower incisor proclination and anterior movement occur after Xbow use (29), (34). Mandibular incisors procline from 4.8° to 9.5° during treatment (34), (32). In general, for orthodontically treated teeth, external apical root resorption is either mild or moderate for 95-99% of teeth (35). Compared to treatment with Forsus springs and brackets, there was no difference in the severity or frequency of orthodontically induced external apical root resorption for Xbow patients (36). Severe resorption exceeding 4mm only occurred in 11% of treated incisors of patients treated with Xbow or Forsus springs, which is consistent with other literature (36).

2.7 Review of Lateral Cephalograms

Cephalometrics was originally introduced by Broadbent in 1931 as a research tool and has evolved into the standard procedure (37), (38). The most significant application of cephalometric radiographs has been in clinical orthodontics (38). Lateral cephalograms are a two-dimensional sagittal depiction of three-dimensional craniofacial structures (39). Identifying anatomical landmarks, in addition to measurements derived from landmarks, are affected by magnification errors (39). Magnification is inherent to the technique of radiographic projection (40). Magnification occurs since X-rays originate from a small source and emit in a non-parallel pattern (41). Overlapping structures superimposed on each other contribute to identification errors (39).

2.8 Review of CBCT

Currently, cone-beam computed tomography (CBCT) is the primary 3-D imaging technique for orthodontics, as CBCT scans significantly reduce the ionizing radiation dose and cost to patients, compared to the gold standard in the medical community which uses advanced fan-beam computed tomography (2). For use in dental applications CBCT has an average effective dose of 20-100 microsieverts compared to medical CT which has an average effective dose of 500-2270 microsieverts (42), (43). One of the main disadvantages of CBCT, compared to

conventional CT images, is that CBCT lack the ability for soft tissue discrimination (43). CBCT scans use a cone-shaped X-ray beam that rotates horizontally around the patient's head, with two-dimensional information as pixels captured on an area detector (2). Software is used to reconstruct the pixel raw projection into 3D volumetric data composed of cuboidal elements called voxels (44). Voxels with a darker grayscale, indicates more radiolucent structures with more radiation reaching the detector (2). CBCTs allow visualization in all three planes of space without magnifications or superimpositions (2). Cone-beam images can display accurate measurements and produce cross-sectional slices at any arbitrary angle (43).

Both spatial and contrast resolutions are important to image clarity in CBCT scans. Spatial resolution distinguishes between separate structures positioned in close proximity (2). The usage of smaller voxel sizes improves spatial resolution (2). Alternatively, contrast resolution distinguishes between tissues of differing densities (2).

A key disadvantage of CBCT, compared to lateral cephalograms and panoramic radiographs, is increased ionizing radiation exposure (2). The amount of ionizing radiation exposure in a CBCT scan depends on the size of the field of view and the resolution required (2). Resolution is inversely correlated to voxel size. Radiation exposure is reduced by limiting the field of view and decreasing resolution by increasing the voxel size (2). The goal is to produce a quality image for accurate diagnosis while exposing the patient to the least radiation as possible.

The American Academy of Oral and Maxillofacial Radiology released a position statement and guidelines for using CBCT in orthodontics in 2013, which was recently updated in 2024 with the most updated evidence-based recommendations (45), (46). The guidelines indicate using the 'as low as reasonably achievable' (ALARA) principle to reduce the dose of ionizing radiation to patients (45). It states there is neither convincing evidence for carcinogenesis at the level of dental exposures nor the absence of evidence for such damage (45). The statement imparts there is no "safety zone" for ionizing radiation exposure and that every exposure cumulatively increases the risk of cancer in a linear model (45). Orthodontic treatment typically occurs in pediatric populations that are 2-10x more prone to radiation-induced carcinogenesis than adults (45).

There is debate over whether the ALARA principle, based on a linear no-threshold hypothesis, is effectively applied in medicine (47). A 2016 paper in *The Journal of Nuclear Medicine* concluded that the linear no-threshold hypothesis is an invalidated hypothesis and ALARA dosing contributes to radiophobia, leading to greater risks to patients by not using this imaging technology (47). It argues that ALARA harms patients by producing suboptimal and even nondiagnostic scans and fails to recognize that the body's defensive response to low-dose radiation is different than the high-dose radiation that the hypothesis is based on (47).

To date, CBCT has been used multiple times to research skeletal and dental changes after the use of the Herbst appliance, but not in Xbow use (24) (48), (49), (50).

2.9 Review of CBCT Landmarking and Measurement Techniques

Before any three-dimensional landmarks are identified, there must be a suitable operational definition of the landmark's location in each of the three planes of space (51). Superimposition of CBCT images at different time points provides a method to assess changes over time, along with treatment effects. Two approaches for CBCT superimposition are voxel-based superimposition and landmark-based superimposition (24).

Voxel-based superimpositions employ cranial base structures compared voxel by voxel after each CBCT acquisition (51). 3D models are superimposed on the best fit of the whole surface of the cranial base for adults and the anterior cranial fossae in growing children (51). The anterior cranial fossae and ethmoid bone are used in growing children since these structures complete growth in early infancy (52). Using superimposed models surface distance calculations can be visualized using color-coded maps to identify treatment outcomes over time (51).

Landmark-based superimpositions illustrate changes by comparing landmark positions to constructed reference planes. One solution to standardize the orientation of 3D images involves using four landmarks located on structures not affected significantly by growth after the age of five (53). These four landmarks (ELSA, rSLEAM, lSLEAM, and MDFM) form both x-y and z-y planes to standardize the orientation of 3D images (53). The x-y plane is formed using ELSA

and both left and right superior-lateral border of the external auditory meatus (53). The z-y plane is formed using 2 landmarks, ELSA and mid-dorsum foramen magnum, by extending the plane from the 2 landmarks so that it is perpendicular to the already established x-y plane (53).

When voxel and landmark based superimpositions are compared, it was found that voxel-based superimposition was both accurate and reliable in detecting changes in landmark positions (54). Landmark-based superimpositions was found to be reliable but less accurate than landmark based superimpositions (54). Another study found similar results that landmark-based superimpositions has a higher measurement error compared to voxel-based superimpositions (55).

Measurements, angles, and volumes are identified in a CBCT image using various techniques. Linear measurements are accurate within two voxels during in vitro testing (56). Measurements can be between reference landmarks and constructed planes. 3-D planes show higher reproducibility when the landmarks used to construct them are located further apart (57). The greater the distance between the landmarks used to construct the planes then small errors in landmark placement have less effect on the overall plane location. Distance is calculated between the same landmark over time using the following equation (24):

$$d = \sqrt{(x1 - x2)^2 + (y1 - y2)^2 + (z1 - z2)^2}.$$

2.10 Summary

Class II malocclusion patients make up a considerable proportion of patients who desire orthodontic treatment. Effective management of these malocclusions is of continued interest to orthodontists. Most existing research regarding growth modification and functional appliances has relied on lateral cephalometry to evaluate treatment outcomes. With the availability of CBCT and the vast amounts of information contained in these scans, innovative approaches and techniques are available to researchers. Additionally, most of the current available studies rely on retrospective data. Although Xbow and Herbst have been compared directly, the comparison has not included a randomized controlled trial or based on CBCT data (22).

References

1. Bishara SE. Class II malocclusions: Diagnostic and clinical considerations with and without treatment. *Seminars in Orthodontics*. 2006;12(1):11–24.
2. Proffit WR, Fields HW, Larson BE, Sarver DM. *Contemporary Orthodontics*. 6th ed. Philadelphia, PA: Elsevier; 2019.
3. McNamara JA, Peterson JE, Alexander RG. Three-dimensional diagnosis and management of Class II malocclusion in the mixed dentition. *Seminars in Orthodontics*. 1996;2(2):114–37.
4. McNamara J. Components of Class II malocclusion in children 8-10 years of age. *Angle Orthodontist*. 1981;51(3):177–202.
5. Illing HM, Morris DO, Lee RT. A prospective evaluation of Bass, Bionator and Twin Block appliances. Part I - the hard tissues. *European Journal of Orthodontics*. 1998;20:501–16.
6. Clark WJ. The twin block technique A functional orthopedic appliance system. 1988;93(1):1-18.
7. Weiland FJ, Ingervall B, Bantleon hans P, Droschl H. Initial effects of treatment of Class II malocclusion with the Herren activator, activator-headgear combination, and Jasper Jumper. *American Journal of Orthodontics and Dentofacial Orthopedics*. 1997;112(1):19–27.
8. Kim-Berman H, McNamara JA, Lints JP, McMullen C, Franchi L. Treatment effects of the Carriere Motion 3D appliance for the correction of Class II malocclusion in adolescents. *Angle Orthodontist*. 2019;89(6):839–46.
9. Ucem TT, Okay C, Gulsen A. Effects of a three-dimensional bimetric maxillary distalizing arch. *European Journal of Orthodontics*. 2000;22:293–8.
10. Ramon Pujols SC, Nogueira CQ, Reis RS, Fonçatti CF, Castanha Henriques JF, Janson G. Stability of Class II malocclusion treatment with the distal jet followed by fixed appliances. *American Journal of Orthodontics and Dentofacial Orthopedics*. 2020;158(3):363–70.
11. Cozza P, Baccetti T, Franchi L, De Toffol L, Mcnamara JA. Mandibular changes produced by functional appliances in Class II malocclusion: A systematic review. 2006;129(5):1-12.
12. D’Antò V, Bucci R, Franchi L, Rongo R, Michelotti A, Martina R. Class II functional orthopaedic treatment: A systematic review of systematic reviews. *Journal of Oral Rehabilitation*. 2015;42(8):624–42.
13. Ishaq RAR, Alhammadi MS, Fayed MMS, El-Ezz AA, Mostafa Y. Fixed functional appliances with multibracket appliances have no skeletal effect on the mandible: A systematic review and

meta-analysis. American Journal of Orthodontics and Dentofacial Orthopedics. 2016;149(5):612–24.

14. Siara-Olds NJ, Pangrazio-Kulbersh V, Berger J, Bayirli B. Long-Term Dentoskeletal Changes with the Bionator, Herbst, Twin Block, and MARA Functional Appliances. Angle Orthodontist. 2010;80(1):18–29.
15. Miller RA, Tieu L, Flores-Mir C. Incisor inclination changes produced by two compliance-free Class II correction protocols for the treatment of mild to moderate Class II malocclusions. Angle Orthodontist. 2013;83(3):431–6.
16. Franchi L, Baccetti T. Prediction of Individual Mandibular Changes Induced by Functional Jaw Orthopedics Followed by Fixed Appliances in Class II Patients. Angle Orthodontist. 2006;76(6):950–4.
17. Camilla Tulloch JF, Phillips C, Koch G, Proffit WR, Hill C, Carolina N. The effect of early intervention on skeletal pattern in Class II malocclusion: A randomized clinical trial. American Journal of Orthodontics and Dentofacial Orthopedics. 1997;111(4):391–400.
18. Pancherz H. The Herbst appliance - Its biologic effects and clinical use. American Journal of Orthodontics. 1985;87(1):1–20.
19. Windmiller EC, Harrisburg M. The acrylic-splint Herbst appliance: A cephalometric evaluation. American Journal of Orthodontics and Dentofacial Orthopedics. 1993;104(1):73–84.
20. Pacha MM, Fleming PS, Pandis N, Shagmani M, Johal A. The use of the Hanks Herbst vs Twin-block in Class II malocclusion: A randomized controlled trial. American Journal of Orthodontics and Dentofacial Orthopedics. 2023;164(3):314–24.
21. Paulsen HU. Orthodontic Treatment of the Class II Noncompliant patient. Papadopoulos MA, editor. Mosby; 2006. p. 35–7.
22. Insabralde NM, Rodrigues de Almeida M, Rodrigues de Almeida-Pedrin R, Flores-Mir C, Castanha Henriques JF. Retrospective comparison of dental and skeletal effects in the treatment of Class II malocclusion between Herbst and Xbow appliances. American Journal of Orthodontics and Dentofacial Orthopedics. 2021;160(4):544–51.
23. Barnett GA, Higgins DW, Major PW, Flores-Mir C. Immediate skeletal and dentoalveolar effects of the crown or banded type Herbst Appliance on Class II division 1 malocclusion A Systematic Review. Angle Orthodontist. 2008;78(2):361–9.

24. Sangalli KL, Dutra-Horstmann KL, Correr GM, Topolski F, Flores-Mir C, Lagravère MO, Moro A. Three-dimensional skeletal and dentoalveolar sagittal and vertical changes associated with cantilever Herbst appliance in prepubertal patients with Class II malocclusion. *American Journal of Orthodontics and Dentofacial Orthopedics*. 2022;161(5):638-651.
25. de Almeida MR, Henriques JFC, de Almeida RR, Ursi W, Mcnamara JA. Short-term treatment effects produced by the Herbst appliance in the mixed dentition. *Angle Orthodontist*. 2005;75(4):540-7.
26. Pancherz H. The mechanism of Class II correction in Herbst appliance treatment: A cephalometric investigation. *American Journal of Orthodontics*. 1982;82(2):104–13.
27. Pancherz H. Treatment of Class II malocclusions by jumping the bite with the Herbst appliance A cephalometric investigation. *American Journal of Orthodontics*. 1979;76(4):423–42.
28. Higgins D. United States Patent. United States: United States Patent; US 6,168,430 B1, 2001. p. 1–9.
29. Flores-Mir C, Barnett G, Higgins DW, Heo G, Major PW. Short-term skeletal and dental effects of the Xbow appliance as measured on lateral cephalograms. *American Journal of Orthodontics and Dentofacial Orthopedics*. 2009;136(6):822–32.
30. Great Lakes Dental Technologies [Internet]. Tonawanda, NY: [publisher unknown]; 2024. Higgins XBOW Class II Corrector. [cited 2024 Jan 14]. Available from: <https://www.greatlakesdentaltech.com/higgins-xbow-class-ii-corrector.html>
31. Xbow® [Internet]. [place unknown]: Crossbow® Orthodontic; 2024. About the Xbow® (Crossbow®) Class II Corrector. [cited 2023 Oct 23]. Available from: <https://crossboworthodontic.com/xbow-class-ii-corrector/>
32. Ehsani S, Nebbe B, Normando D, Lagravere MO, Flores-Mir C. Dental and skeletal changes in mild to moderate Class II malocclusions treated by either a Twin-block or Xbow appliance followed by full fixed orthodontic treatment. *Angle Orthodontist*. 2015;85(6):997–1002.
33. Flores-Mir C, McGrath LM, Heo G, Major PW. Efficiency of molar distalization with the XBow appliance related to second molar eruption stage. *European Journal of Orthodontics*. 2013;35(6):745–51.
34. Flores-Mir C, Young A, Greiss A, Woynorowski M, Peng J. Lower incisor inclination changes during Xbow treatment according to vertical facial type. *Angle Orthodontist*. 2010;80(6):1075–80.

35. Tieu LD, Saltaji H, Normando D, Flores-Mir C. Radiologically determined orthodontically induced external apical root resorption in incisors after non-surgical orthodontic treatment of class II division 1 malocclusion: a systematic review. *Progress in Orthodontics*. 2014;15:48.
36. Tieu L, Normando D, Toogood R, Flores-Mir C. External apical root resorption generated by Forsus simultaneously with brackets vs. Xbow followed by brackets to correct Class II malocclusions. *Journal of the World Federation of Orthodontists*. 2015;4:120–3.
37. Broadbent BH. A new X-ray technique and its application to orthodontia. *Angle Orthodontist*. 1931;1(2):45–66.
38. Ricketts RM. Perspectives in the clinical application of cephalometrics: The first fifty years. *Angle Orthodontist*. 1981;51(2):115–50.
39. Chien PC, Parks ET, Eraso F, Hartsfield JK, Roberts WE, Ofner S. Comparison of reliability in anatomical landmark identification using two-dimensional digital cephalometrics and three-dimensional cone beam computed tomography in vivo. *Dentomaxillofacial Radiology*, 2009;38(5):262–73.
40. H Dibbets JM, Nolte K, Marburg D. Effect of magnification on lateral cephalometric studies. 2002;122(2):196-201.
41. Baumrind S, Frantz RC. The reliability of head film measurements 1. Landmark identification. *American Journal of Orthodontics*. 1971;60(2):111–27.
42. Zaman MU. Comparing radiation doses in CBCT and medical CT imaging for dental applications. *Journal of Pharmacy and Bioallied Sciences*. 2024;16(1):883–5.
43. White SC. Cone-beam imaging in dentistry. *Health Physics*. 2008;95(5):628–37.
44. Scarfe WC, Angelopoulos C. *Maxillofacial Cone Beam Computed Tomography: Principles, Techniques and Clinical Applications*. New York City (NY): Springer; 2018. p. 13-41.
45. Scarfe WC. Clinical recommendations regarding use of cone beam computed tomography in orthodontics. Position statement by the American Academy of Oral and Maxillofacial Radiology. *Oral Surg Oral Med Oral Pathol Oral Radiol*. 2013;116(2):238–57.
46. Benavides E, Krecioch JR, Connolly RT, Allareddy T, Buchanan A, Spelic D, O’Brien KK, Keels MA, Mascarenhas AK, Duong M, Aerne-Bowe MJ, Ziegler KM, Lipman RD. Optimizing radiation safety in dentistry Clinical recommendations and regulatory considerations. *The Journal of the American Dental Association*. 2024;155(4)280-293.

47. Siegel JA, Pennington CW, Sacks B. Subjecting radiologic imaging to the linear no-threshold hypothesis: A non sequitur of non-trivial proportion. *The Journal of Nuclear Medicine*. 2017;58:1–6.
48. Fan Y, Schneider P, Matthews H, Roberts WE, Xu T, Wei R, Claes P, Clement J, Kilpatrick N, Penington A. 3D assessment of mandibular skeletal effects produced by the Herbst appliance. *BMC Oral Health*. 2020;20:2-9.
49. Cheib PL, Cevidanes LHS, Ruellas AC de O, Franchi L, Braga WFM, Oliveira D, Souki BQ. Displacement of the mandibular condyles immediately after Herbst appliance insertion - 3D assessment. *Turkish Journal of Orthodontics*. 2016;29(2):31–7.
50. Lecornu M, Cevidanes LHS, Zhu H, Wu C Da, Larson B, Nguyen T. Three-dimensional treatment outcomes in Class II patients treated with the Herbst appliance: A pilot study. *American Journal of Orthodontics and Dentofacial Orthopedics*. 2013;144(6):818–30.
51. Cevidanes LHS, Styner MA, Proffit WR. Image analysis and superimposition of 3-dimensional cone-beam computed tomography models. *American Journal of Orthodontics and Dentofacial Orthopedics*. 2006;129(5):611–8.
52. Cevidanes LHC, Heymann G, Cornelis MA, DeClerck HJ, Tulloch JFC. Superimposition of 3-dimensional cone-beam computed tomography models of growing patients. *American Journal of Orthodontics and Dentofacial Orthopedics*. 2009;136(1):94–9.
53. Lagravère MO, Hansen L, Harzer W, Major PW. Plane orientation for standardization in 3-dimensional cephalometric analysis with computerized tomography imaging. *American Journal of Orthodontics and Dentofacial Orthopedics*. 2006;129(5):601–4.
54. Ghoneima A, Cho H, Farouk K, Kula K. Accuracy and reliability of landmark-based, surface-based and voxel-based 3D cone-beam computed tomography superimposition methods. *Orthodontics & Craniofacial Research*. 2017;20:227–36.
55. Ponce-Garcia C, Ruellas ACDO, Cevidanes LHS, Flores-Mir C, Carey JP, Lagravere-Vich M. Measurement error and reliability of three available 3D superimposition methods in growing patients. *Head & Face Medicine*. 2020;16:1-20.
56. Pinsky HM, Dyda S, Pinsky RW, Misch KA, Sarment D. Accuracy of three-dimensional measurements using cone-beam CT. *Dentomaxillofacial Radiology*. 2006;35:410–6.
57. Shibata M, Nawa H, Kise Y, Fuyamada M, Yoshida K, Katsumata A, Arijji E, Goto S. Reproducibility of three-dimensional coordinate systems based on craniofacial landmarks A

tentative evaluation of four systems created on images obtained by cone-beam computed tomography with a large field of view. Angle Orthodontist. 2012;82(5):776-784.

Chapter 3: Skeletal and Dental Changes During Treatment of Moderate Class II Malocclusions with Fixed Class II Correctors: A Randomized Controlled Trial

3.1 Introduction

Class II malocclusions are common, occurring in nearly one-third of the American population (1). E.H. Angle classified a Class II malocclusion when the mandibular molars are positioned distally relative to the maxillary molars (2). Skeletally, a Class II relationship is most often due to mandibular retrusion, however a transverse maxillary discrepancy is common (3), (1). Treatment to camouflage a Class II malocclusion can involve using a functional appliance to posture the mandible into a downward and forward position (4). There is controversy in published literature whether Class II functional appliances stimulate mandibular growth. Some evidence shows mandibular advancement relative to the cranial base and increased mandibular length when using functional appliances (5). Alternatively, contrary evidence shows that fixed functional appliances do not produce significant positional or dimensional skeletal effects on the mandible with no significant long-term dentoskeletal changes (6), (7). It has been reported that 23% to 80% of Class II malocclusion corrections from functional appliances are due to dental changes (8). Functional appliances, considered as a group, significantly decrease the overjet by causing proclination of the lower incisors and retroclination of the upper incisors (5).

The Herbst appliance was first introduced by Emil Herbst in 1905 and reintroduced to the orthodontic community by Pancherz in 1979 (9), (10). There are many variations of Herbst appliances, generally categorized into four basic designs: banded, cast splint, stainless steel crown, and acrylic splint (11). The Herbst appliance is categorized as a passive tooth-borne functional appliance (2). It is deemed passive because of its dependence on soft tissue stretch and muscular activity to produce treatment effects, not an intrinsic force-generating capacity of the telescoping mechanism (2). The appliance advances the mandible repositioning the mandible anteriorly and downward, continuously displacing the condyles away from the glenoid fossa (12). Herbst appliances can be incrementally activated using crimpable shims (13). Herbst appliances do not rely on patient adherence, but one issue that can arise is partial breakage (2). Treatment times for Herbst appliances range from 8-12 months with the goal to overcorrect to account for 1-2mm of relapse (2). Skeletally there is minimal effect on the maxilla which does

not show a “headgear effect” (14). It has been reported by Pancherz that Herbst use increased the mandibular size by 2.2mm, while Windmiller reported a 3.4mm increase (15) (16) (10). Herbst Class II correction is primarily through dentoalveolar effects (14). The maxillary molars move distally (2.8mm) while mandibular molars move anteriorly (1.0mm) compared to a control group (16). Maxillary incisors retrocline (3.8°) and move posteriorly, while mandibular incisors are proclined, (4-6.6 $^{\circ}$) and move anteriorly. (17) (12) (18).

The Xbow, patented in the U.S. in 2001 by Dr. Duncan W. Higgins, is used in late mixed or early permanent dentition as a Phase 1 appliance (19), (20). The Xbow is categorized as a non-protrusive inter-arch Class II malocclusion corrector (20). Since the mandible is not held rigidly forward, the patient can function in centric occlusion (20). The Xbow is a relatively new fixed class II corrector; the initial research article was published in 2009 (20). Since then, multiple studies have since been released (21), (22), (23), (18), (24), (20), (12), (25), (26), (27). Xbow use has short treatment times for Class II correction of mild/moderate malocclusions with a mean of 4.5 months (20). The Xbow treatment protocol includes overcorrecting to a partially Class III molar relationship with maxillary first premolars in an end-to-end Class III relationship with the mandibular second premolars which accounts for relapse (20). Overall, the Xbow accomplishes Class II malocclusion correction with primarily dental rather than skeletal changes. Xbow treatment has a “headgear effect” by not only restricting maxillary skeletal anterior movement but actually displacing it posteriorly 1.2mm compared to a control group (20). The Xbow distalizes maxillary molars an average of 1.7mm which was similar if second molars were erupted during treatment or not (26). In an initial study, the Xbow reduced overjet by a total of 3mm, primarily caused by dental movements (20). Sixty percent of the overjet reduction was due to equal amounts of maxillary incisors moving posteriorly while mandibular incisors moved anteriorly (20). Xbow treatment results in a small amount of anterior movement of mandibular first molars (0.6mm) with a greater amount of posterior movement of maxillary first molars (2.0-3.9mm) (20), (12). Consistent with other Class II correctors, lower incisors procline (4.8° to 9.5°) and move anteriorly during Xbow use (20), (24), (27).

Currently the published research has shortcomings that this study aimed to address. Although Cone-beam computed tomography (CBCT) was first introduced to the dental field in 1999,

orthodontic research is still primarily based on lateral cephalograms (28). CBCT has been used to research skeletal and dental changes after the use of Herbst appliances (14), (29), (30), (31). On the other hand, only one study has been published using CBCT for the Xbow with the primary focus on upper airway dimensions rather than skeletal and dental changes (22). Use of CBCT can add value to the current understanding of the skeletodental effects of appliances as the results can be evaluated in three dimensions, which is not possible with two dimensional lateral cephalograms.

Another shortcoming of the current publications involves a lack of prospective clinical trials with control groups included. Retrospective studies have an inferior level of evidence compared to a randomized clinical trial and they can be subject to increased bias. Another major issue with retrospective trials is either not including a control group or selecting patients from a database to include as a control group. This makes comparisons between the experimental groups and the control group challenging and the resulting conclusions less meaningful.

Currently there is only one study that directly compares the skeletal and dental effects of both the Herbst and Xbow appliances. In 2021, Insabralde et al, published a retrospective study that compared the effects of the Herbst and Xbow appliances utilizing lateral cephalograms and a historical control group obtained from the Burlington Growth Study (12).

The objective of the current study was to evaluate the 3D skeletal and dental changes of Herbst and Xbow treatment utilizing a randomized controlled prospective design with an included control group.

3.2 Methods

The study was a randomized clinical trial with three groups.

Group 1 - Herbst appliance group with roughly 12 months of appliance wear.

Group 2 - Xbow appliance group with roughly 12 months of appliance wear.

Group 3 – Comparison control group with full fixed bonded braces for 12 months with no intermaxillary elastics.

Inclusion criteria for participants was as follows:

- Class II malocclusion with severity of at least an end-to-end molar relationship.
- Female patients in age range ten to fourteen years old, or male patients eleven to sixteen years old.
 - Age ranges selected to include the 3 stages of adolescence growth in girls and the 4 stages of adolescent growth in boys (2).
- Late mixed or early permanent dentition with maxillary first molars and first premolars erupted.
- Overjet greater than or equal to 1mm.
- Overbite greater than or equal to 1mm.
- ANB angle greater than or equal to 4°.

Exclusion criteria for participants was as follows:

- Known craniofacial anomalies or syndromic patients.
- Gingival recession below the cemento-enamel junction.
- Previous history of temporomandibular joint pathology or trauma.
- Crowding of 6mm or more in either maxillary or mandibular arch.
- Congenitally missing teeth (excluding third molars).

Ethics approval was obtained from the University of Alberta's Health Research Ethics Board with the study ID Pro00045191. This randomized controlled trial was registered with the ISRCTN and was assigned the study number 42366.

The sample size was determined to include a total of 90 participants (30 per group), which considers if there is a 20% dropout rate each group would still contain 24 patients. A closely related randomized clinical trial involving the Xbow appliance, conducted at the University of Alberta (study ID Pro00021423), quantified that a sample with 25 participants per group (before 20% assumed loss) is adequate to investigate dental and skeletal changes.

Block randomization was utilized to ensure equal numbers in each of the three experimental groups. A statistician compiled the list of patient codes in sealed envelopes which indicated the group each patient was assigned to. Subjects were recruited from University of

Alberta, Graduate Orthodontic Graduate Program patient pool. An experienced orthodontist completed a clinical examination and explained the study to potential subjects. Informed consent for subjects who chose to participate in the study was obtained by a research assistant. The research assistant would then provide the subjects with their sealed envelope that indicated what study group and code number the patient would be assigned to.

The treatment protocol for the control group included alignment only with no Class II mechanics. On the first day, both upper and lower arches were bonded with 3M™ Victory Series™ self ligating 0.022" slot brackets. Archwires were changed roughly every 8 weeks (after assessment that changing wire was appropriate by the orthodontist) following the sequence 0.014" NiTi (nickel titanium), 0.018" NiTi, 0.016" x 0.022" NiTi, 0.020" x 0.020" Niti and 0.019" x 0.025" NiTi. 15 out of the 19 participants ended with 0.020" x 0.020" or 0.019" x 0.025" Niti wires. Brackets were removed after twelve months of treatment and Phase 1 debond records are completed.

The design used for the Herbst appliance was a stainless-steel crown type. After impressions and dental stone casts were produced, the laboratory fits crowns on all four first molars. In the maxilla, a rapid maxillary expander (Hyrax) is incorporated across the palate connected to the first molar crowns. The mandibular portion includes a lingual holding arch with cantilever arms extending from the buccal surface of the first molar crowns to the first premolar area. Both arches include occlusal rests on the first premolars and the second molars (if erupted). Patients have separators placed mesial and distal to first molars one week prior to the Herbst appliance insertion. Both upper and lower arch components are bonded and Hyrax expansion starts the first day with an appropriate numbers of turns prescribed by the orthodontist to be completed 1 turn per day. The mean expansion prescribed was 6.1mm with a standard deviation of 1.0mm. After four weeks the Herbst telescoping rods are secured to the maxillary crowns and the mandibular cantilever arms utilizing locking screws. At this same appointment 15 out of the 21 participants had either maxillary lateral incisor to lateral incisor bonding or canine to canine bonding to ensure adequate overjet for Class II correction. The decision whether bonding was necessary or not was made by the orthodontist clinically. The patient is recalled every eight weeks and 2mm shims are added bilaterally to the telescoping rods for increased activation.

Activation ceased once the molars were overcorrected to a half cusp Class III relationship. The average amount of activation in this group was 5.3mm (SD = 2.3) over an average amount of time of 7.6 months (SD = 2.5). At twelve months the Herbst appliance is removed and Phase 1 debond records are completed.

The Xbow appliance is fabricated by fitting bands on the mandibular and maxillary first molars following adequate separation of the teeth. Impressions are taken and submitted to the lab where dental casts are produced and fabrication occurs. In the maxilla, a Hyrax is included across the palate and the bands include headgear tubes. In the mandible both a labial and lingual arch connect to the molar bands and 3M™ Unitek™ Gurin locks are located on the labial bow in the first premolar region. In both arches occlusal rests are located on the first premolars and the second molars (if erupted). Separators need to be replaced mesial and distal to the first molars one week prior to the insertion appointment. Both upper and lower arch components are bonded and Hyrax expansion starts the first day with an appropriate number of turns prescribed by the orthodontist to be completed 1 turn per day. The mean expansion prescribed was 6.2mm with a standard deviation of 1.0mm. After four weeks a measurement is taken to ensure the proper length of the Forsus® arm is selected and the Forsus® springs are added to the headgear tubes and distal to the Gurin locks. At this same appointment 10 out of the 19 participants had either maxillary lateral incisor to lateral incisor bonding or canine to canine bonding to ensure adequate overjet for Class II correction. The decision whether bonding was necessary or not was made by the orthodontist clinically. The patient is recalled every 8 weeks and the Gurin locks were moved usually 2mm distally for increased activation. Activation ceased once the molars were overcorrected to a half cusp Class III relationship. The average amount of activation in this group was 3.4mm (SD = 1.9) over an average amount of time of 5.7 months (SD = 1.4). At twelve months the Xbow appliance is completely removed and Phase 1 debond records are completed.

Large field of view CBCT scans utilizing an i-CAT 17-19 by Imaging Sciences International at medium resolution (voxel size 0.3 mm and 8.9 seconds) were taken for each subject before treatment (T₁) and after the 12-month treatment period of appliance or braces wear (T₂). Patients were positioned with Frankfort horizontal plane parallel to the floor in maximum intercuspation with tongue placed behind the upper central incisors and patients were asked not

to swallow during the scan. Scans stored as DICOM files. Patients were recalled every 8 weeks during treatment.

The radiology technician anonymized the DICOM files using the assigned patient code. Both T1 and T2 anonymized CBCTs were provided to the primary investigator responsible for landmarking. Only after landmarking was complete and patient group was necessary for statistical analysis did the investigator received a master list revealing the patients assigned treatment group.

CBCTs were uploaded to Dolphin 3D® software (Version 11.95) and reoriented in three planes prior to landmarking. Images were reoriented in frontal view so the axial plane intersected the inferior border of each orbit, in the right view so axial plane lies on Frankfort Horizontal plane intersecting both porion and orbitale, and in the top view (facing down) so mid-sagittal plane intersects anterior nasal spine and bisects the foramen magnum. Following reorientation, CBCTs exported as a DICOM file.

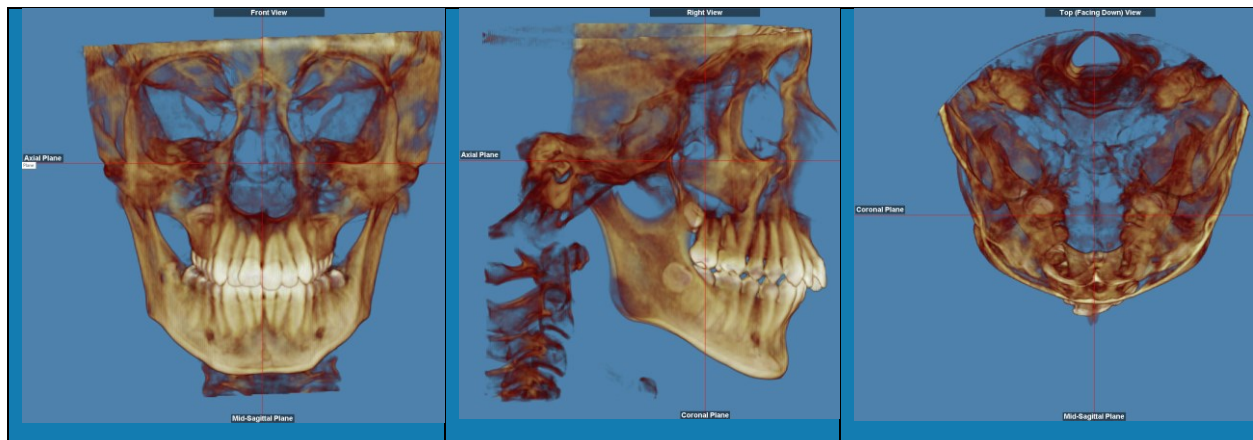








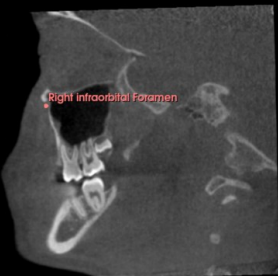


Figure 1. Orientation of CBCT scans. Front, Right and Top Views.

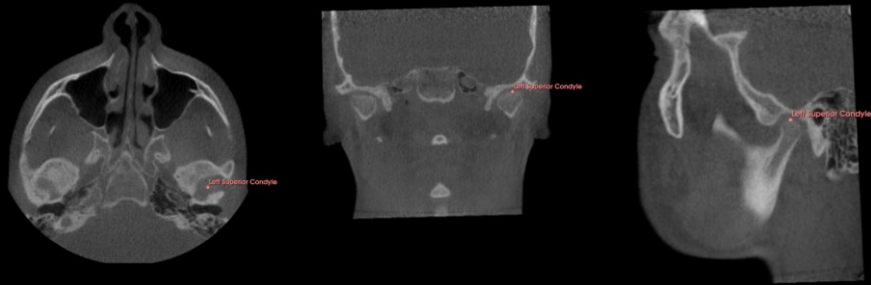An open-source software 3D Slicer (Version 5.0.3) was used to landmark CBCTs. In total, 34 landmarks identified, with 18 skeletal and 16 dental landmarks. T1 and T2 for all 59 patients were landmarked. Descriptions of each landmark location found in Figure 2.

Landmark Description	Axial View	Coronal View	Sagittal View
Foramen Spinosum (Left and Right): Center of small opening at the base of the skull anterior to the spine of the sphenoid and posterior-lateral to the foramen ovale.			
ELSA: Point located between left and right foramina spinosa.			
Infraorbital Foramen (Left and Right): Center of the foramen on the outer most aspect of the maxillary bone located inferior to the orbit.			

Superior Condyle

(Left and Right):

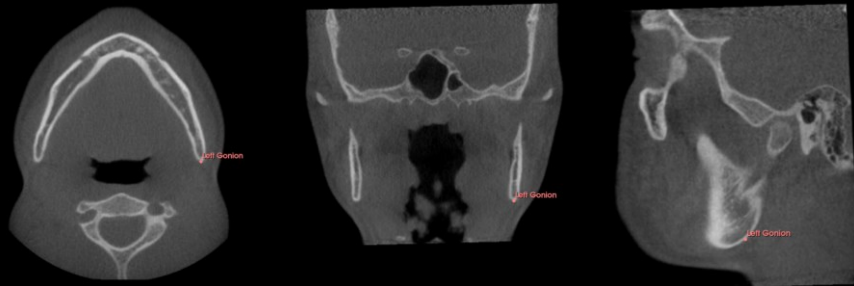Most superior point of condyle.

**Gonion (Left and**

Right):

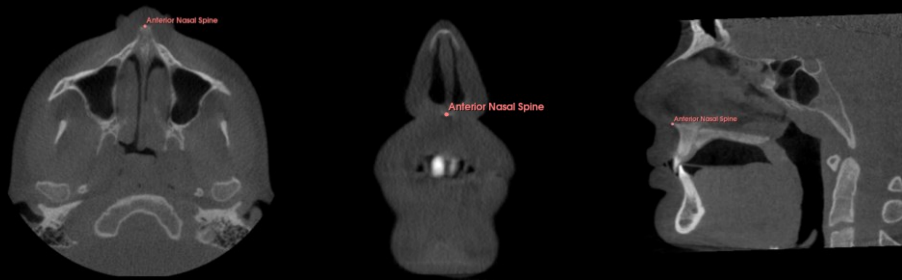
Most posterior and inferior point of mandibular ramus.


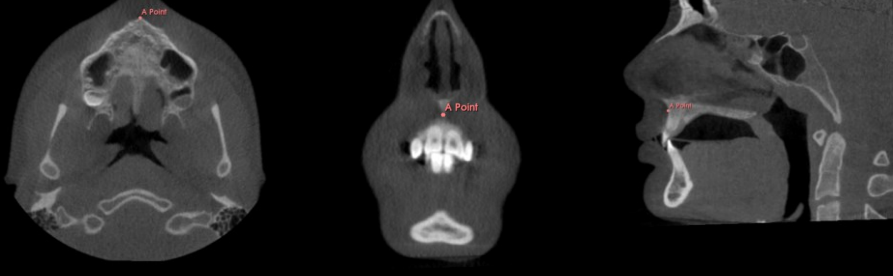

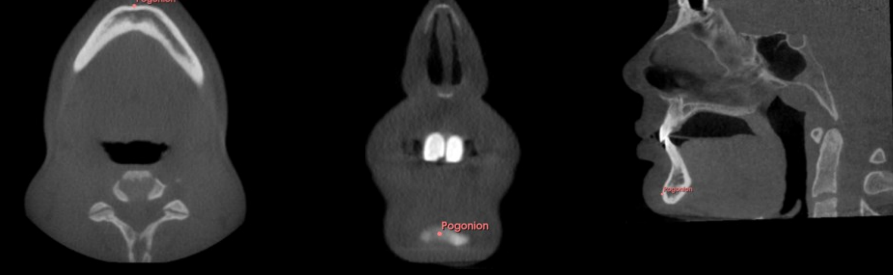
Located in the most convex region along the inferior border of the ramus.




**Anterior Nasal**

Spine:

Anterior end of the nasal spine. Most anterior point of maxillary bone.

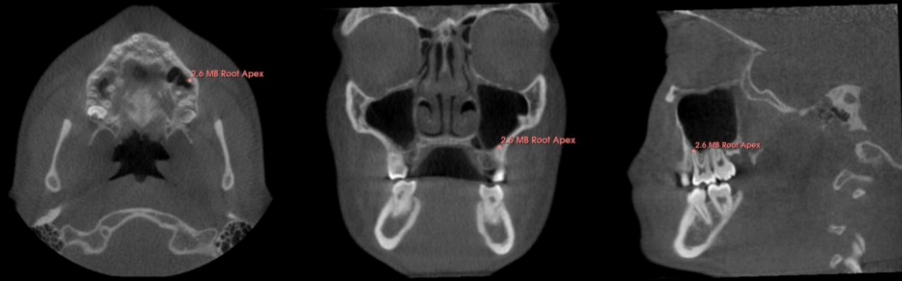

<p>Posterior Nasal Spine:</p> <p>Posterior end of posterior nasal spine. Most posterior point of palatine bone.</p>	
<p>A Point:</p> <p>Deepest point in the concavity from the anterior nasal spine to the alveolar ridge.</p>	
<p>B Point:</p> <p>Deepest point in the concavity from the alveolar ridge to the chin.</p>	
<p>Pogonion:</p> <p>Most anterior point of the mandibular symphysis in the median sagittal plane.</p>	

<p>External Auditory Canal (Left and Right):</p> <p>Point located in the most external and posterior region of the external auditory canal.</p>	
<p>Foramen Magnum:</p> <p>Midpoint of the anterior curvature of the Great foramen.</p>	
<p>Nasopalatine Foramen:</p> <p>Center of inferior opening of foramen located posterior to the maxillary central incisors at the palatal midline.</p>	

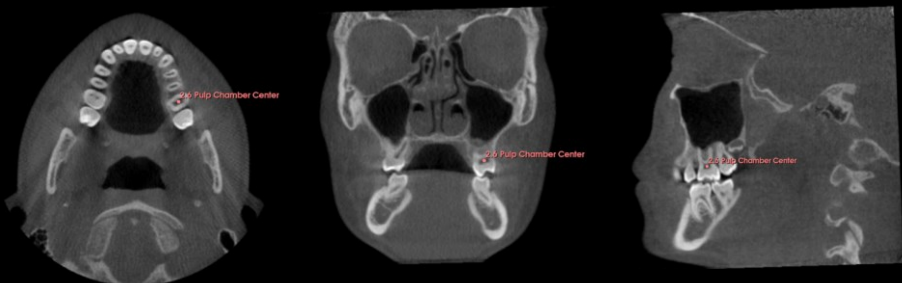**Maxillary First
Molar Mesio Buccal
Root Apex** (Left and
Right):

Termination of
mesio buccal root.



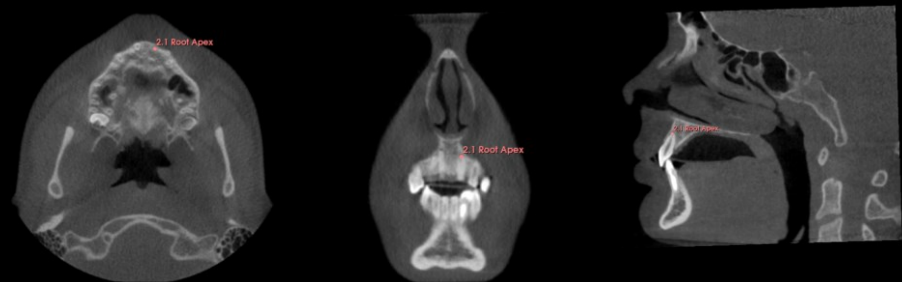**Maxillary First
Molar Pulp
Chamber Center**
(Left and Right):

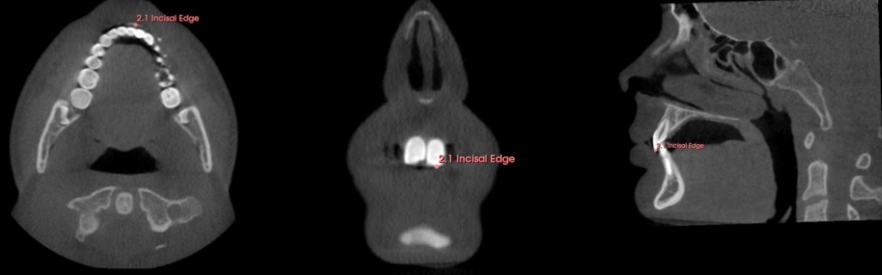



Center of the largest
axial, sagittal, and
coronal section of the
pulp chamber area.

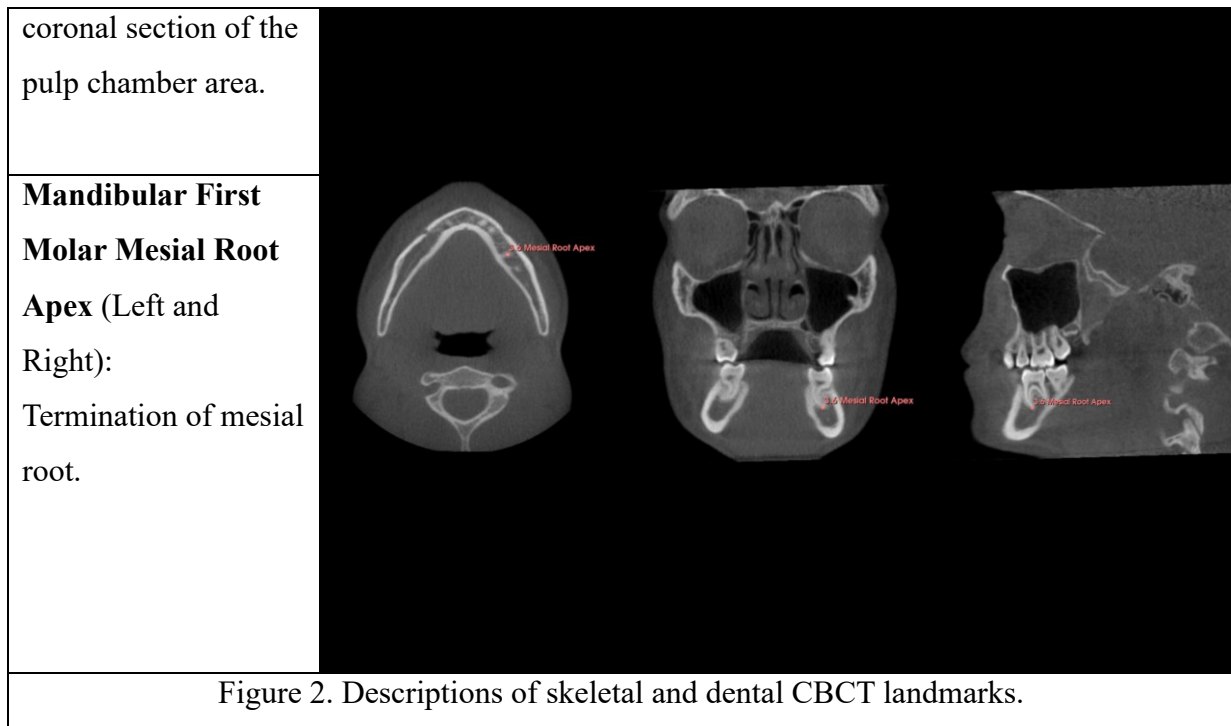


**Maxillary Central
Incisor Root Apex**
(Left and Right):

Termination of root.



<p>Maxillary Central Incisor Incisal Edge (Left and Right): Point in the center of the incisal edge.</p>	
<p>Mandibular Central Incisor Incisal Edge (Left and Right): Point in the center of the incisal edge.</p>	
<p>Mandibular Central Incisor Root Apex (Left and Right): Termination of root.</p>	
<p>Mandibular First Molar Pulp Chamber Center (Left and Right): Center of the largest axial, sagittal, and</p>	



To assess if changes occur over time, a linear distance measurement between each landmark and 3-D planes created using three skeletal landmarks was measured. Landmarks used for each plane are shown in Figure 3 along with visual aids of plane location. Reference plane landmarks were chosen as much as possible in the anterior cranial base since growth in this area is mostly completed by age 7, resulting in stable landmarks even in an otherwise growing population (32). With the exception of the nasopalatine foramen, the other 6 landmarks used for 3-D plane creation were the same as the skull base reference points used by Sangalli et al. to create a 3D coordinate system and orient planes (14).

The sagittal plane was created to measure transverse changes over time using landmarks: ELSA, foramen magnum, and nasopalatine foramen. All three structures are in the midline. ELSA was established by Dr. Lagravere in 2005 as an adequate landmark for 3D analysis which has high reliability (33).

The coronal plane was created to measure anteroposterior changes over time using landmarks: Nasopalatine foramen, right infraorbital foramen, and left infraorbital foramen. Although the created plane is not perfectly perpendicular to the Frankfort Horizontal plane, these

three landmarks were used since they are easily identifiable and the resulting slope of plane is minimal.

The axial plane was created to measure vertical changes over time using landmarks: Left external auditory canal, right external auditory canal, and ELSA.

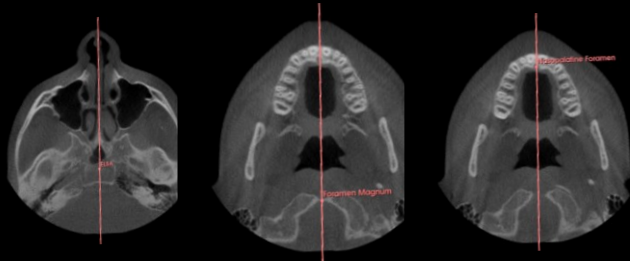

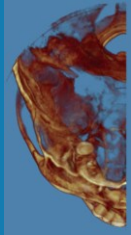
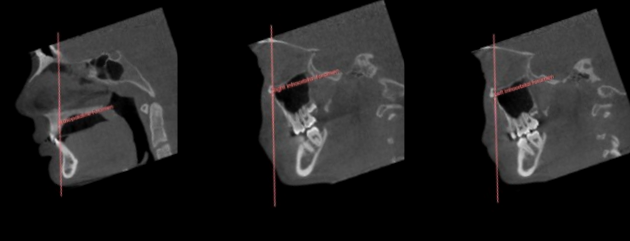
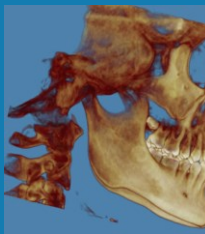
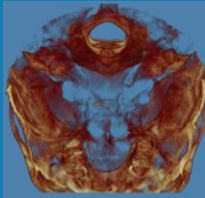
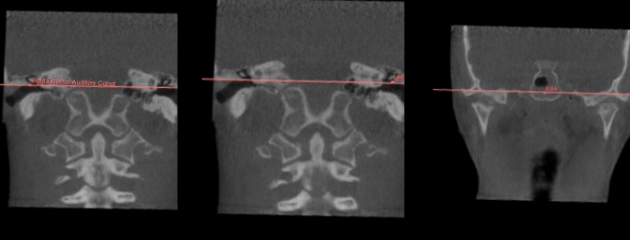
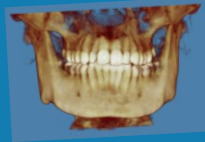

Plane	Landmark 1	Landmark 2	Landmark 3	3D Representations	
Sagittal					
	ELSA	Foramen Magnum	Nasopalatine Foramen	Frontal View	Top View
Coronal					
	Nasopalatine Foramen	Right Infraorbital Foramen	Left Infraorbital Foramen	Right View	Top View
Axial					
	Right External Auditory Canal	Left External Auditory Canal	ELSA	Front View	Right View

Figure 3. Landmarks used to create each 3D reference plane. Sagittal plane is reference for transverse measurements. Coronal plane is reference for anteroposterior movement measurements. Axial plane is for vertical measurements.

The linear distance from each landmark to each of the three 3-D planes was calculated for both T1 and T2. Coordinates (X, Y, Z) for each landmark was recorded in a Microsoft Excel spreadsheet along with information of which 3 coordinates make up each plane. Using a previously developed MATLAB software tool (by MathWorks®) the perpendicular distance of each landmark to each reference plane was computed. The mathematical equations in MATLAB were developed as part of two previous research projects conducted at the University of Alberta (34), (35). The distance T1 was subtracted from the distance of T2 to determine the change in landmark location during the study. For transverse measurements a positive T2-T1 means the landmark moved laterally away from the midline. For vertical measurements a positive T2-T1 means the landmark moved inferiorly. For anteroposterior measurements it must be considered if the landmark lies in front of or behind the 3-D plane. For landmarks located anteriorly relative to the plane, for example the anterior nasal spine, then a positive T2-T1 means the landmark has moved anteriorly. Alternatively, if the landmark is located posteriorly to the plane, for example gonion, then a positive T2-T1 means the landmark has moved posteriorly.

To assess mandibular growth two aspects of the mandible were measured using CBCT landmarks: ramus height and mandibular body length. Ramus height is measured between right/left gonion and right/left superior condyle and an average of the two values was calculated. Mandibular body length is measured between left/right gonion and pogonion, similarly an average value was calculated. Both mandibular dimensional lengths were calculated using the formula $d = \sqrt{(x1 - x2)^2 + (y1 - y2)^2 + (z1 - z2)^2}$ with the x, y, z coordinates of both landmarks (14). Then the distance of T1 was subtracted from the distance of T2 to determine if any increase in either mandibular body length or ramus height occurred.

Proclination of the lower incisors is seen generally among fixed class II correctors, so IMPA (Incisor Mandibular Plane Angle) was measured at both T1 and T2. Although, IMPA can be calculated exclusively using 3-D landmarks it was determined to be simpler and easier to

instead create a lateral cephalogram from the CBCT and calculate IMPA from the 2-D image. On the lateral cephalograms four landmarks were located to calculate IMPA: gonion, pogonion, lower incisor root apex, and lower incisor incisal tip. T1 IMPA was subtracted from T2 IMPA to determine the amount of increased proclination of the lower incisors following treatment.

3.3 Statistical Analysis

Statistical analysis was carried out using IBM SPSS Statistics version 29.0.2.0 (IBM Corp.©) and unless otherwise stated the significance level was set at $\alpha = 0.05$. The null hypothesis tested is that treatment with the Herbst or Xbow appliance does not cause skeletal or dental changes compared to normally growing patients.

Intra-examiner reliability

Intra-examiner reliability for CBCT landmarking was tested using Intraclass Correlation Coefficient (ICC) using 10 random CBCTs landmarked at 3 different times spaced at least one week apart. The ICC is reported for each of X, Y, Z coordinates for all 34 landmarks along with 95% confidence intervals and average standard deviations. The results were evaluated according to Portney and Watkin's ICC guidelines (Table 1). The results are considered in excellent agreement for any ICC above 0.90 (36).

Additionally, intra-examiner reliability was tested using ICC for lateral cephalograms derived from the same 10 random CBCTs that were landmarked at 3 different times spaced at least one week apart. The ICC is reported for the X and Y coordinates for all 4 landmarks along with 95% confidence intervals and average standard deviations.

Table 1. Intra-class Correlation Coefficient (ICC) guidelines according to Portney and Watkin

ICC>0.90	Excellent Agreement
0.75<ICC<0.89	Good Agreement
0.51<ICC<0.74	Moderate Agreement
ICC<0.50	Poor Agreement

Factor Variables

In this study there are three factor variables:

- 1) Appliance with three levels: Control group, Herbst group, Xbow group.
 - a) Appliance is considered a between-subject factor.
- 2) Time with two levels: T1 (before treatment) and T2 (after treatment).
 - a) Time is considered a within-subject factor, but since the statistical analysis used T2-T1, the factor of time was basically eliminated.
- 3) Landmarks with 32 landmarks identified
 - a) Landmarks are considered a within-subject factor

One-way MANOVA at T1

A one-way MANOVA was conducted to determine if the three experimental group's landmark locations were similar at T1. Since the stability of cranial base landmarks has been established in the literature and this is not a research objective they were not included in the analysis.

Even with sample sizes between groups being similar we must be cautious drawing conclusions from the data, since our total sample of 59 patients is relatively low compared to the 81 total variables after cranial base landmarks removed. Generally, a subject-to-variables ratio of at least 5 is recommended, while our subject-to-variable ratio is 0.7 (37).

Assumptions testing for the one-way MANOVA at T1 is summarized in Table 9 in the appendix.

One-way MANOVA for T2-T1

To determine if there were differences between the groups after treatment, the T2-T1 for each landmark in each of the three directions was calculated. A one-way MANOVA, with the same four assumptions as above, was used to see if the treatment group's landmarks differed following appliance use. Since forces are applied symmetrically left vs. right side of patients, landmarks with a left/right were paired into a single average distance from the plane. This was done as focus of research is what occurs in maxillary molars not specifically right and left molars specifically as an example (Table 2).

Similarly to the T1 MANOVA, even with similar sample sizes between groups we must be cautious drawing conclusions from the data since our total sample of 59 patients is relatively low compared to the 49 variables. Generally, a subject-to-variables ratio of at least 5 is recommended, while our subject-to-variable ratio is 1.2 (37).

Assumptions testing for the one-way MANOVA for T2-T1 were conducted using same process as T1 MANOVA and details specific to the T2-T1 test included in Table 10 in the appendix.

Skeletal Landmarks	Dental Landmarks
Average Superior Condyle	Average Mx 1 st Molar Root Apex
Average Gonion	Average Mx 1 st Molar Pulp Chamber Center
Anterior Nasal Spine	Average Mx Central Incisor Root Apex
Posterior Nasal Spine	Average Mx Central Incisor Incisal Edge
A Point	Average Md Central Incisor Incisal Edge
B Point	Average Md Central Incisor Root Apex
Pogonion	Average Md 1 st Molar Pulp Chamber Center
Nasopalatine Foramen	Average Md 1 st Molar Root Apex
Table 2. Average paired landmark list.	

One-way Repeated Measures ANOVA Test

Seven separate one-way repeated measures ANOVA tests were conducted to assess whether there are any differences in the skeletal transverse, skeletal anteroposterior, skeletal vertical, dental transverse, dental anteroposterior, dental vertical, or mandibular length/height/IMPA parameters from T2 to T1 between the Control, Herbst and Xbow groups. Bonferroni post hoc testing was completed for any one-way repeated measure ANOVA that showed statistically significant changes between the three experimental groups.

Assumptions testing for one-way repeated measures ANOVA test are summarized in Table 15 in appendix.

3.4 Results

Table 3. Descriptive Statistics of the Sample.

	Control Group	Herbst Group	Xbow Group
Sample Size	19	21	19
Male:Female	11:8	9:12	12:7
Mean age at T1 with Standard Deviation (years)	13.1 (SD = 1.1)	13.3 (SD = 1.2)	12.8 (SD = 1.1)
Time Between T1 to T2 (years)	1.0	1.2	1.0
Mean ANB angle at T1 (°)	4.9 (SD = 2.0)	5.2 (SD = 2.2)	5.1 (SD = 2.0)
Mean Overjet at T1 (mm)	4.6 (SD = 2.1)	7.1 (SD = 3.6)	7.2 (SD = 2.1)
Mean Amount of Class II Molar Relationship at T1 (mm)	4.4 (SD = 1.7)	6.0 (SD 0.9)	4.9 (SD 1.4)
Mean Time Appliance Active (months)	N/A	7.6 (SD = 2.5)	5.7 (SD = 1.4)
Mean Amount of Activation (mm)	N/A	5.3 (SD = 2.3)	3.4 (SD = 1.9)
Mean Expansion Prescribed (mm)	N/A	6.1 (SD = 1.0)	6.2 (SD = 0.9)

Originally the plan was to include 90 patients in the study according to the previously determined sample size calculation. Due to time constraints a total of 59 participants were recruited as shown in table 19 in the appendix.

3.4.1 Intra-examiner reliability

Table 20 in the appendix summarized CBCT landmark ICC results. Overall, the ICC results were excellent as for all 34 landmarks the ICC was above 0.90. The lowest X coordinate ICC was 0.966 [0.908, 0.991] on the right superior condyle. The lowest Y coordinate ICC was 0.970 [0.906, 0.992] on the right gonion. The lowest Z coordinate ICC was 0.985 [0.955, 0.996] on the right gonion.

Table 21 in the appendix summarized the lateral cephalogram landmark ICC results. Similarly, the ICC results were excellent for the 4 landmarks all being above 0.90. The lowest X coordinate ICC was 0.977 [0.830, 0.995] for the lower incisor root tip. The lowest Y ICC was also found on the lower incisor root tip 0.978 [0.900, 0.995].

3.4.2 Results of One-way MANOVA at T1

The one-way MANOVA was carried out to determine whether there are mean differences among the three treatment groups at T1. Due to small sample size, we grouped all the variables into four groups with a smaller number of variables in each group, and four separate one-way MANOVAs were run (Sagittal, AP, Axial, Mandible Dimensions and IMPA) with each resulting in a p value > 0.05 showing no statistically significant differences between groups (Table 11 in appendix).

3.4.3 Results of One-way MANOVA for T2-T1

The one-way MANOVA was carried out to determine whether there are mean differences among the three treatment groups after T2-T1. Due to small sample size, we grouped all the variables into four groups with a smaller number of variables in each group, and four separate one-way MANOVAs were run (Sagittal, AP, Axial, Mandible Dimensions and IMPA) with each resulting in a p value < 0.001 showing statistically significant differences between groups (Table 13 in appendix).

Skeletal Results

3.4.4 Results of One-way Repeated Measures ANOVA Test and Bonferroni Post Hoc Testing

1) Skeletal Vertical

Mauchly's test of sphericity indicated that the assumption of sphericity had been violated, $\chi^2(20) = 172.758$, $p = <0.001$ (Table 16 in appendix). Thus, we report and interpret ANOVA p-values with Greenhouse and Geisser epsilon (ϵ) correction. The experimental intervention did not lead to any statistically significant changes in the skeletal landmarks in a sagittal direction, $F(5.295, 148.259) = 1.473$, $p = 0.199$ (Table 17 in appendix). P values reported in Table 17 are interaction terms, and since no statistically significant changes present, no post hoc tests were completed.

2) Skeletal Anteroposterior

Mauchly's test of sphericity indicated that the assumption of sphericity had been violated, $\chi^2(20) = 245.811$, $p = <0.001$ (Table 16 in appendix). Thus, we report and interpret ANOVA p-values with Greenhouse and Geisser epsilon (ϵ) correction. The skeletal landmarks show weak evidence they are different after experimental intervention in an anteroposterior direction, $F(4.086, 114.400) = 2.631$, $p = 0.037$ (Table 17 in appendix). The reason it is weak evidence with a Greenhouse-Geisser p-value of 0.037 is that an α of 0.025 was used rather than the traditional α of 0.05. The α was divided by 2 since statistical analysis was carried out for skeletal and dental landmarks separately. This controls the overall Type I error rate and prevents inflating false positive error rate. The p-value of 0.037 falls just above the α of 0.025, which indicates weak evidence of changes present, so Bonferroni post hoc comparisons were completed.

The statistically significant changes in landmarks include (Table 4):

- Gonion
 - Herbst group moved 2.1mm more anteriorly compared to the Control group. 95% CI [0.872, 3.258], $p < 0.001$.
 - Herbst group moved 1.2mm more anteriorly compared to the Xbow group. 95% CI [0.052, 2.438], $p = 0.038$.
- Posterior Nasal Spine
 - Herbst group moved 0.8mm more anteriorly compared to the Control group, 95% CI [0.257, 1.370], $p = 0.002$.
 - Xbow group moved 0.7mm more anteriorly compared to the Control group, 95% CI [0.130, 1.270], $p = 0.011$.
- B Point
 - Herbst group moved 1.6mm more anteriorly compared to the Control group, 95% CI [0.060, 3.076], $p = 0.039$.
- Pogonion
 - Herbst moved 1.8mm more anteriorly compared to the Control group, 95% CI [0.120, 3.471], $p = 0.032$.

Table 4. Bonferroni Post Hoc Test for Skeletal Landmarks Anteroposterior Direction

Landmark	Comparison (A to B)	Mean Difference (mm) (A-B)	p value	95% CI
Superior Condyle	Control to Herbst	0.414	0.908	[-0.568, 1.396]
	Control to Xbow	0.246	0.999	[-0.760, 1.252]
	Xbow to Herbst	0.168	0.999	[-0.814, 1.150]
Gonion	Control to Herbst	2.065	<0.001	[0.872, 3.258]
	Control to Xbow	0.820	0.310	[-0.403, 2.042]
	Xbow to Herbst	1.245	0.038	[0.052, 2.438]
Anterior Nasal Spine	Herbst to Control	0.012	0.999	[-0.477, 0.500]
	Xbow to Control	0.128	0.999	[-0.373, 0.629]
	Xbow to Herbst	0.116	0.999	[-0.372, 0.605]
Posterior Nasal Spine	Control to Herbst	0.813	0.002	[0.257, 1.370]
	Control to Xbow	0.700	0.011	[0.130, 1.270]
	Xbow to Herbst	0.113	0.999	[-0.443, 0.669]
A Point	Control to Herbst	0.020	0.999	[-0.423, 0.463]
	Control to Xbow	0.184	0.966	[-0.270, 0.638]
	Herbst to Xbow	0.164	0.999	[-0.279, 0.607]
B Point	Control to Herbst	1.568	0.039	[0.060, 3.076]
	Control to Xbow	1.003	0.344	[-0.542, 2.548]
	Xbow to Herbst	0.564	0.999	[-0.944, 2.072]
Pogonion	Control to Herbst	1.795	0.032	[0.120, 3.471]
	Control to Xbow	0.935	0.553	[-0.782, 2.653]
	Xbow to Herbst	0.860	0.632	[-0.816, 2.536]

3) Skeletal Vertical

Mauchly's test of sphericity indicated that the assumption of sphericity had been violated, $\chi^2(27) = 213.206$, $p = <0.001$ (Table 16 in appendix). Thus we report and interpret ANOVA p-values with Greenhouse and Geisser epsilon (ϵ) correction. The experimental intervention did not

lead to any statistically significant changes in the skeletal landmarks in an axial direction, $F(6.072, 170.019) = 1.106$, $p = 0.361$ (Table 17 in appendix). Since no statistically significant changes present, no post hoc tests were completed.

Dental Results

4) Dental Transverse

Mauchly's test of sphericity indicated that the assumption of sphericity had been violated, $\chi^2(27) = 88.080$, $p = <0.001$ (Table 16 in appendix). Thus, we report and interpret ANOVA p-values with Greenhouse and Geisser epsilon (ϵ) correction. The dental landmarks are statistically significantly different after experimental intervention in the transverse direction, $F(10.054, 281.517) = 13.897$, $p < 0.001$ (Table 17 in appendix). Since statistically significant changes present, Bonferroni post hoc comparisons completed.

The statistically significant changes in landmarks include (Table 5):

- Maxillary First Molar Root Apex
 - Herbst group moved 1.1mm more laterally compared to the Control group. 95% CI [0.518, 1.590], $p < 0.001$.
 - Xbow group moved 1.4mm more laterally compared to the Control group. 95% CI [0.840, 1.938], $p < 0.001$.
- Maxillary First Molar Pulp Chamber
 - Herbst group moved 1.8mm more laterally compared to the Control group. 95% CI [1.336, 2.312], $p < 0.001$.
 - Xbow group moved 2.0mm more laterally compared to the Control group. 95% CI [1.489, 2.489], $p < 0.001$.
- Mandibular First Molar Root Apex
 - Herbst group moved 0.7mm more laterally compared to the Xbow group. 95% CI [0.256, 1.174], $p < 0.001$.

Table 5. Bonferroni Post Hoc Test for Dental Landmarks Transverse Direction

Landmark	Comparison (A to B)	Mean Difference (mm) (A-B)	p value	95% CI
U6 Root Apex	Herbst to Control	1.054	<0.001	[0.518, 1.590]
	Xbow to Control	1.389	<0.001	[0.840, 1.938]
	Xbow to Herbst	0.335	0.387	[-0.201, 0.871]
U6 Pulp Chamber	Herbst to Control	1.824	<0.001	[1.336, 2.312]
	Xbow to Control	1.989	<0.001	[1.489, 2.489]
	Xbow to Herbst	0.165	0.999	[-0.323, 0.653]
U1 Root Apex	Herbst to Control	0.380	0.152	[-0.090, 0.850]
	Xbow to Control	0.429	0.097	[-0.053, 0.910]
	Xbow to Herbst	0.048	0.999	[-0.422, 0.518]
U1 Incisal Edge	Control to Herbst	0.088	0.999	[-0.278, 0.454]
	Control to Xbow	0.042	0.999	[-0.333, 0.417]
	Xbow to Herbst	0.045	0.999	[-0.320, 0.411]
L1 Incisal Edge	Control to Xbow	0.037	0.999	[-0.169, 0.242]
	Herbst to Control	0.119	0.443	[-0.081, 0.320]
	Herbst to Xbow	0.156	0.180	[-0.045, 0.357]
L1 Root Apex	Control to Xbow	0.158	0.999	[-0.405, 0.722]
	Herbst to Control	0.069	0.999	[-0.481, 0.619]
	Herbst to Xbow	0.227	0.939	[-0.323, 0.777]
L6 Pulp Chamber	Control to Herbst	0.232	0.237	[-0.088, 0.551]
	Control to Xbow	0.208	0.368	[-0.120, 0.536]
	Xbow to Herbst	0.024	0.999	[-0.296, 0.343]
L6 Root Apex	Control to Xbow	0.326	0.279	[-0.145, 0.796]
	Herbst to Control	0.389	0.122	[-0.069, 0.848]
	Herbst to Xbow	0.715	<0.001	[0.256, 1.174]

5) Dental Anteroposterior

Mauchly's test of sphericity indicated that the assumption of sphericity had been violated, $\chi^2(27) = 326.618$, $p = <0.001$ (Table 16 in appendix). Thus, we report and interpret ANOVA p-values with Greenhouse and Geisser epsilon (ϵ) correction. The dental landmarks are statistically significantly different after experimental intervention in the anteroposterior direction, $F(4.775, 133.687) = 6.613$, $p < 0.001$ (Table 17 in appendix). Since statistically significant changes present, Bonferroni post hoc comparisons completed.

The statistically significant changes in landmarks include (Table 6):

- Maxillary First Molar Root Apex
 - Herbst group moved 0.7mm more anterior compared to the Control group. 95% CI [0.131, 1.180], $p = 0.010$.
- Maxillary First Molar Pulp Chamber
 - Herbst group moved 1.4mm more posterior compared to the Control group. 95% CI [0.700, 2.020], $p < 0.001$.
 - Xbow group moved 1.9mm more posterior compared to the Control group. 95% CI [1.231, 2.584], $p < 0.001$.
- Maxillary Central Incisor Incisal Edge
 - Xbow group moved 1.9mm more posterior compared to the Control group. 95% CI [0.158, 3.558], $p = 0.028$.
- Mandibular Central Incisor Incisal Edge
 - Herbst group moved 2.4 mm more anterior compared to the Control group. 95% CI [0.856, 3.884], $p < 0.001$.
 - Xbow group moved 2.6 mm more anterior compared to the Control group. 95% CI [1.046, 4.149], $p < 0.001$.
- Mandibular First Molar Pulp Chamber
 - Herbst group moved 2.0mm more anterior compared to the Control group. 95% CI [0.570, 3.512], $p = 0.003$.
 - Xbow group moved 2.5mm more anterior compared to the Control group. 95% CI [1.042, 4.057], $p < 0.001$.
- Mandibular First Molar Root Apex

- Xbow group moved 1.7mm more anterior compared to the Control group. 95% CI [0.117, 3.298], $p = 0.031$.

Table 6. Bonferroni Post Hoc Test for Dental Landmarks Anteroposterior Direction

Landmark	Comparison (A to B)	Mean Difference (mm) (A-B)	p value	95% CI
U6 Root Apex	Control to Herbst	0.655	0.010	[0.131, 1.180]
	Control to Xbow	0.429	0.162	[-0.109, 0.966]
	Xbow to Herbst	0.227	0.873	[-0.298, 0.751]
U6 Pulp Chamber	Herbst to Control	1.360	<0.001	[0.700, 2.020]
	Xbow to Control	1.908	<0.001	[1.231, 2.584]
	Xbow to Herbst	0.548	0.136	[-0.112, 1.208]
U1 Root Apex	Herbst to Control	0.031	0.999	[-0.800, 0.863]
	Xbow to Control	0.213	0.999	[-0.639, 1.065]
	Xbow to Herbst	0.182	0.999	[-0.650, 1.013]
U1 Incisal Edge	Control to Herbst	1.123	0.301	[-0.536, 2.782]
	Control to Xbow	1.858	0.028	[0.158, 3.558]
	Herbst to Xbow	0.734	0.838	[-0.925, 2.393]
L1 Incisal Edge	Herbst to Control	2.370	<0.001	[0.856, 3.884]
	Xbow to Control	2.598	<0.001	[1.046, 4.149]
	Xbow to Herbst	0.227	0.999	[-1.287, 1.742]
L1 Root Apex	Control to Herbst	0.774	0.699	[-0.811, 2.360]
	Xbow to Control	0.106	0.999	[-1.519, 1.730]
	Xbow to Herbst	0.880	0.529	[-0.706, 2.466]
L6 Pulp Chamber	Control to Herbst	2.041	0.003	[0.570, 3.512]
	Control to Xbow	2.549	<0.001	[1.042, 4.057]
	Herbst to Xbow	0.508	0.999	[-0.963, 1.979]
L6 Root Apex	Control to Herbst	1.486	0.065	[-0.067, 3.038]
	Control to Xbow	1.708	0.031	[0.117, 3.298]

	Herbst to Xbow	0.222	0.999	[-1.330, 1.774]
--	----------------	-------	-------	-----------------

6) Dental Vertical

Mauchly's test of sphericity indicated that the assumption of sphericity had been violated, $\chi^2(27) = 217.656$, $p = <0.001$ (Table 16 in appendix). Thus, we report and interpret ANOVA p-values with Greenhouse and Geisser epsilon (ϵ) correction. The dental landmarks are statistically significantly different after experimental intervention in the vertical direction, $F(7.230, 202.435) = 4.970$, $p < 0.001$ (Table 17 in appendix). Since statistically significant changes present, Bonferroni post hoc comparisons completed.

The statistically significant changes in landmarks include (Table 7):

- Maxillary Central Incisal Edge
 - Xbow group extruded 2.5mm compared to the Control group. 95% CI [0.188, 4.853], $p = 0.030$.
- Mandibular Central Incisal Edge
 - Xbow group intruded 3.8mm compared to the Control group. 95% CI [1.059, 6.618], $p = 0.004$.

Table 7. Bonferroni Post Hoc Test for Dental Landmarks Vertical Direction

Landmark	Comparison (A to B)	Mean Difference (mm) (A-B)	p value	95% CI
U6 Root Apex	Control to Herbst	0.906	0.339	[-0.483, 2.294]
	Xbow to Control	0.014	0.999	[-1.409, 1.437]
	Xbow to Herbst	0.920	0.323	[-0.469, 2.308]
U6 Pulp Chamber	Control to Herbst	0.972	0.255	[-0.396, 2.340]
	Control to Xbow	0.624	0.829	[-0.778, 2.026]
	Xbow to Herbst	0.348	0.999	[-1.020, 1.716]
U1 Root Apex	Herbst to Control	0.546	0.999	[-1.095, 2.188]
	Xbow to Control	1.082	0.354	[-0.600, 2.764]

	Xbow to Herbst	0.535	0.999	[-1.106, 2.177]
U1 Incisal Edge	Herbst to Control	1.280	0.512	[-0.996, 3.557]
	Xbow to Control	2.520	0.030	[0.188, 4.853]
	Xbow to Herbst	1.240	0.553	[-1.037, 3.516]
L1 Incisal Edge	Herbst to Control	2.032	0.209	[-0.681, 4.744]
	Xbow to Control	3.839	0.004	[1.059, 6.618]
	Xbow to Herbst	1.807	0.317	[-0.905, 4.519]
L1 Root Apex	Herbst to Control	0.324	0.999	[-2.037, 2.686]
	Xbow to Control	1.315	0.556	[-1.105, 3.735]
	Xbow to Herbst	0.991	0.914	[-1.371, 3.353]
L6 Pulp Chamber	Herbst to Control	0.695	0.999	[-1.429, 2.818]
	Xbow to Control	1.579	0.236	[-0.597, 3.755]
	Xbow to Herbst	0.884	0.925	[-1.239, 3.008]
L6 Root Apex	Control to Herbst	0.170	0.999	[-1.668, 2.008]
	Xbow to Control	0.299	0.999	[-1.584, 2.182]
	Xbow to Herbst	0.469	0.999	[-1.368, 2.307]

7) Mandibular Body Length, Ramus Height, IMPA

Mauchly's test of sphericity indicated that the assumption of sphericity had been violated, $\chi^2(2) = 72.790$, $p = <0.001$ (Table 16 in appendix). Epsilon (ϵ) was 0.577, as calculated according to Greenhouse and Geisser, and was used to correct the one-way repeated measures ANOVA. The changes are statistically significantly different after experimental intervention for these three measures, $F(2.307, 64.598) = 13.777$, $p < 0.001$ (Table 17 in appendix). Since statistically significant changes present Bonferroni post hoc comparisons completed.

The statistically significant changes in landmarks include (Table 8):

- Incisor Mandibular Plane Angle (IMPA)
 - Herbst group increased lower incisor proclination by 9.3° compared to the Control group. 95% CI [4.307, 14.270], $p < 0.001$.
 - Xbow group increased lower incisor proclination by 10.0° compared to the Control group. 95% CI [4.864, 15.073], $p < 0.001$.

Table 8. Bonferroni Post Hoc Test for Mandibular Body Length, Ramus Height, IMPA

Landmark	Comparison (A to B)	Mean Difference (A-B)	p value	95% CI
IMPA	Herbst to Control	9.288°	<0.001	[4.307, 14.270]
	Xbow to Control	9.968°	<0.001	[4.864, 15.073]
	Xbow to Herbst	0.680°	0.999	[-4.302, 5.662]
Mandible Body Length	Control to Herbst	0.354 mm	0.866	[-0.461, 1.168]
	Xbow to Control	0.283 mm	0.999	[-0.552, 1.117]
	Xbow to Herbst	0.636 mm	0.177	[-0.178, 1.117]
Mandible Ramus Height	Control to Herbst	0.299 mm	0.999	[-0.932, 1.531]
	Xbow to Control	0.067 mm	0.999	[-1.195, 1.328]
	Xbow to Herbst	0.366 mm	0.999	[-0.865, 1.597]

Table 9. Overall ANB Angle, Molar Relationship and Overjet Change

	Control Group	Herbst Group	Xbow Group
Mean ANB decrease (°)	0.0 (SD = 1.56)	1.2 (SD = 1.6)	0.6 (SD = 0.7)
Mean Molar Relationship Change (mm)	0.0 (SD = 0.8)	9.8 (SD = 3.4)	7.2 (SD = 2.7)
Mean Decrease in Overjet (mm)	-0.5 (SD = 1.0) *	6.2 (SD = 3.3)	5.2 (SD = 2.2)
* negative value indicates an increase in overjet			

3.5 Discussion

There has only been one previous study that has directly compared the effects of the Herbst and Xbow appliances (12). The trial design involved lateral cephalogram radiography with a retrospective cohort and an untreated control group selected from the longitudinal growth study sample from the University of Toronto Burlington Growth Study (12). This study design has several limitations. In general, retrospective studies have an inferior level of evidence

compared to prospective studies. Retrospective trials are associated with inflated treatment effects when compared to prospective trials (38). Selection bias is a common concern when evaluating retrospective studies, with randomization impossible to achieve. Insabralde et al. had different clinicians treat the Herbst and Xbow groups (12). Since there can be considerable variability of training and techniques among orthodontists, this can be a confounding variable between treatment groups. Using the Burlington Growth Study patients to procure an untreated control group is not ideal. This assembled control group was 6 months older than the mean ages of the Herbst or Xbow groups and was followed for 6 months longer overall. To compare the control group measurements were adjusted to a timeframe similar to the 1.28 years that the Herbst and Xbow groups were treated which introduces error. It must also be considered that since the Burlington Growth Study started in the 1950s and that maturational timing of children has shifted to earlier maturation it can be problematic to compare a dated control group to current treatment groups (39). The lateral cephalograms were taken on different machines for each of the three compared groups and although the magnification factors were corrected, the possibility of radiographic differences still persists.

Our study is unique since it is a randomized controlled trial that utilized CBCT imaging and included a treated control group for direct comparison to the Herbst and Xbow appliance groups. The control group estimates what average growth would occur in these patients while completing level and alignment and provide a baseline to show the true effect of the Xbow and Herbst appliances. High-quality, randomized controlled trials are integral to evidence-based medicine and form the backbone of future systematic reviews, which should be at the forefront of evidence-based decision making (40).

Prior to discussing the treatment effects, there must be consideration of the difference between statistically significant results and clinically significant results. Results that are statistically significant may be small in magnitude and be inconsequential in the decision-making process of a clinician treating patients. Clinicians must factor in many variables beyond differences in treatment outcome, for example: cost, ease of fabrication, ease of insertion, ease of repair, patient cleansibility, frequency/severity of emergency visits, and patient comfort. These factors will take higher priority in deciding what appliance is appropriate for a patient if the

overall skeletal and dental differences between appliances are similar. Cozza et al. used 2.0mm as the clinically significant difference for mandibular dimension changes between treated and untreated groups (41). Insabralde et al. used 3.6mm as their clinically meaningful difference for the measurement of condylion to pogonion which serves to assess overall mandible size. For the purpose of discussion, we adopted 2.0mm as a baseline for clinically meaningful change. The rationale is that if 4mm of anterior mandibular change, resulting from 2mm dental and 2mm skeletal, is combined with 4mm of posterior maxillary change, resulting from 2mm dental and 2mm skeletal, then a cumulative 8mm of Class II correction could occur. 8mm would undoubtedly be clinically significant as it would facilitate full cusp Class II correction. In terms of incisor mandibular plane angle (IMPA) a clinically significant change of 5° was used. Ellis and McNamara used a range of 4.5° (89° to 93.5°) to categorize patients with a “neutral” relationship of mandibular incisors to the mandible (42). Burden et al. stated that a 5 degree increase in incisor proclination is needed for every 2mm of overjet reduction (above 4mm of overjet) (43). Given the normal range of IMPA and that a clinically significant 2mm reduction is possible with 5° of incisor proclination it was felt that 5° is a reasonable amount of angular change in IMPA to be clinically significant.

Beginning with skeletal changes between groups, it is important to note what changes were not observed. No significant changes were noted in the transverse or vertical directions for any skeletal landmarks. The force vector of both Class II corrector appliances is to posture the mandible in a forward and downward direction, so it is unsurprising that no transverse changes were noted skeletally (4). Even with the downward component of force no vertical skeletal changes were observed, likely due to the appliance designs with more horizontally directed forces than vertically. Additionally, no increase of mandibular body length or ramus height was observed for either the Herbst or Xbow groups. With no increased dimensional size of the mandible our results are consistent with Ishaq et al. that concluded fixed-functional appliances do not have a significant dimensional skeletal effect on the mandible (6). These results run contrary to Pancherz (2.2mm) and Insabralde et al. (4.71mm) that both reported increased mandibular size using the measurement condylion-pogonion (Co-Pog) (15), (12). When, comparing the results of our study with previously reported values, the differences in measuring technique using CBCT images must be considered. The Co-Pog measurement is a linear

measurement taken off a 2D lateral cephalogram radiograph with superimposed structures that measures from the condyle to the symphysis to indicate overall mandibular size. By utilizing CBCT, superimposition of structures is eliminated, and the measurements can consider the transverse dimension for more accurate measurements. Additionally, instead of measuring Co-Pog, our measurements of mandibular size took into account where mandibular growth would occur, whether ramus height or mandibular body length instead of overall mandibular size. It is also interesting to note that our randomized controlled trial results were consistent with the results of the systematic review of Ishaq et al. which only included randomized clinical trials and prospective controlled clinical trials or fixed functional appliances (6). This raises the possibility that study design influences the magnitude of results reported.

The only statistically significant skeletal directional changes were in the anteroposterior dimension, but most would not be clinically significant. The Herbst group had anterior movement of landmarks gonion (2.1mm), B point (1.6mm), and pogonion (1.8mm). All three landmarks are mandibular and considering no significant dimensional increase of the mandible it can be concluded that there was a small anterior mandibular positional change in the Herbst group. Only gonion exceeds the 2mm threshold of clinical significance so the effect of mandibular positional changes is minor. In a thesis completed in 2022 that examined condylar positioning following treatment with Herbst and Xbow appliances, there was no significant positional change of the condyle relative to the fossa when compared to control patients (44). This indicates that condyle displacement is not a significant factor in Class II correction with fixed Class II appliances. Posterior nasal spine moved anteriorly in both the Herbst (0.8mm) and the Xbow group (0.7mm), but both were clinically insignificant changes. Further investigation is needed to determine why the posterior nasal spine moved anteriorly when typically, a headgear effect is expected with Class II correctors (45). One proposed theory is that after transverse expansion with midpalatal suture separation there could be a positional change of the posterior nasal spine during bone remodelling to fill in the open palatal suture.

Dental changes in a transverse dimension can be explained by the effects of the incorporated expanders in both the Herbst and Xbow designs. Class II patients commonly have a transverse maxillary discrepancy, so expansion is often prescribed (1). Some effects of expansion

include lateral movement and buccal crown tipping of maxillary molars (46). In both the Xbow and Herbst group the U6 molar root moved laterally (1.1mm Herbst, 1.4mm Xbow) and the U6 crowns, represented by pulp chamber landmark, moved even further laterally (1.8mm Herbst, 2.0mm Xbow). With both the root and crowns moving laterally there was bodily translation, and with the crowns displaced further than the roots, U6 crowns tipped buccally. The dental transverse changes generally of a small magnitude with minimal clinical significance.

Proclination of the mandibular incisors were quite similar between the Xbow and Herbst groups. The incisor mandibular plane angle increased 9.3° in the Herbst group and 10.0° in the Xbow group. The proclination is consistent with Insabralde et al., but twice the magnitude with their results of 4.7° for the Herbst appliance and 4.3° for the Xbow appliance (12). There were no significant differences in study design, appliance design, or additional lower incisor control measures which would account for this difference. The proclination in our Xbow group was more than twice the magnitude reported by Miller et al. of 4.8° (18). Similarly, our Herbst group reported twice the magnitude of proclination reported by de Almeida et al. of 5.0° (47). It must also be considered that as the control group had full bonding and resolution of crowding that the lower incisor incisors would procline. Since the Herbst and Xbow proclination is relative to the control group with braces that the true proclination is likely larger than the reported 9.3° - 10.0° if a completely untreated control group was utilized.

Consistent with expected results of mandibular incisor proclination the mandibular incisal edge moved 2.6mm anteriorly and intruded 3.8mm in the Xbow group with no significant movement of roots, indicating dental tipping. While in the Herbst group the lower incisal edge moved 2.4mm anteriorly with no significant vertical changes. With similar force vectors applied in both the Herbst and Xbow appliance it is not apparent why significant intrusion occurred in the mandibular incisors after Xbow treatment. Further research could focus on this finding.

A difference between the Xbow and Herbst outcomes was in the maxillary central incisors. There were no significant changes for the Herbst group in either a vertical or anteroposterior direction. On the other hand, in the Xbow group the incisal edge moved 1.9mm posteriorly and extruded 2.5mm. Both these Xbow findings can be explained by retroclination of

the maxillary incisors which is consistent with the results of Flores-Mir et al. with retroclination and posterior movement of the maxillary incisors, with the caveat being, that in his study the differences were not enough to be statistically significant (20).

For Class II dental correction, ideally for molar movements, maxillary molars would move bodily posteriorly while mandibular molars would move bodily anteriorly. For the Xbow group, bodily anterior movement occurred in the mandibular molars with posterior movement occurring in the maxillary molars with distal tipping of the crowns. Mandibular molar crowns (represented by pulp chamber landmark) moved 2.5mm anteriorly and the roots moved 1.7mm anteriorly. There is some mesial tipping, but primarily the mandibular crowns are translated anteriorly. The maxillary molars in the Xbow group showed distal crown tipping with the crowns moving 1.9mm posteriorly with no significant change in root position. The Herbst group showed significant distal tipping of the maxillary molars and mesial crown tipping of mandibular molars. Herbst maxillary molar crowns moved 1.4mm posteriorly with the roots moving 0.7mm anteriorly showing distal tipping of the molars with the crowns and roots moving in opposite directions. Herbst mandibular molar crowns moved 2.0mm anteriorly with no significant change to the root apex illustrating mesial crown tip.

Overall, the treatment of Class II malocclusions with Herbst and Xbow appliances produce primarily dental changes favorable to Class II correction. Skeletal changes were only noted in the Herbst appliance in the anteroposterior direction with the magnitude being small enough that clinical significance is debateable. No change to mandibular body length or ramus height occurred in any treatment group. Similar to the conclusion made by Insabralde et al., there are subtle differences between the effects of the Xbow and Herbst appliance (12). The change observed in each measurement alone is not a meaningful Class II improvement, but when all the changes are observed together significant Class II correction is possible. Overall, the outcome differences between these two appliances are small in number and magnitude, leaving a clinician to rely on personal preference when deciding which appliance to use. Rather than minute differences in clinical outcomes, the choice to use the Herbst or Xbow appliance will likely prioritize fabrication, repair, insertion/removal, patient experience/comfort, costs and risk of emergency visits.

3.6 Limitations

Similar to all research studies, there are limitations that must be considered in this study including:

1. Sample size. Recognizing that 59 patients total for a randomized controlled trial is difficult and expensive to attain, with three treatment groups and numerous landmarks to investigate the statistical conclusions would be more powerful with a larger sample.
2. The results of this study do not address long-term or even short-term stability. Since the T2 radiographs were taken immediately following Xbow or Herbst removal 12-months into treatment, this does not allow for relapse to occur or reduction in patient posturing prior to taking the T2 radiograph. This has potential to overstate the results. Additionally, this study only considers appliance wear, not the results after full comprehensive treatment is complete.
3. Control group. Ideally the comparison group would have no treatment with simply a CBCT taken at T1 and a year later at T2 with only the effects of growth accounted for. To decrease overall treatment time, the control group had full bonding of brackets, which undoubtedly causes dental changes as leveling and aligning occurs. It is not expected that skeletal changes (other than growth) occurred in the control group. No inter-arch mechanics were used in the control group, to minimize the effects of orthodontic intervention and to provide an accurate baseline of growth to compare to the functional appliances.
4. The selection of landmarks for creation of the coronal plane for anteroposterior measurements. Using the landmarks of right and left infraorbital foramen and the nasopalatine foramen result in a plane that does not run fully perpendicular to the Frankfort Horizontal plane (see Figure 3). The angled plane results in a slightly decreased amount of the true anteroposterior movement being reported, but the reported amount was consistent between the three treatment groups.

3.7 Conclusions

Neither the Xbow or the Herbst appliance cause increased mandibular dimensions of mandibular body length or ramus height that are clinically relevant. Minor skeletal changes in an

anteroposterior direction occurred after use of the Herbst appliance. Overall, dental changes were similar for both the Herbst and Xbow groups including: lower incisor proclination, lateral movement of molars due to incorporated expanders, distal tipping of maxillary molars. Additional retrusion and retroclination of maxillary incisors occurred in the Xbow group. In the Xbow group, the mandibular molars moved bodily anteriorly while the Herbst group had mesial crown tipping. Taken individually, the effect of each measurement's contribution to Class II correction is negligible, but cumulatively the effects of both the Xbow and Herbst contribute to Class II correction primarily through dental correction. With the differences between the Xbow and Herbst being so small, clinical considerations will likely serve as the key factor for orthodontists in choosing which appliance to use.

3.8 References

1. McNamara JA, Peterson JE, Alexander RG. Three-dimensional diagnosis and management of Class II malocclusion in the mixed dentition. *Seminars in Orthodontics*. 1996;2(2):114–37.
2. Proffit WR, Fields HW, Larson BE, Sarver DM. *Contemporary Orthodontics*. 6th ed. Philadelphia, PA: Elsevier; 2019.
3. Bishara SE. Class II malocclusions: Diagnostic and clinical considerations with and without treatment. *Seminars in Orthodontics*. 2006;12(1):11–24.
4. Proffit WR, Fields HW, Larson BE, Sarver DM. *Contemporary Orthodontics*. 6th ed. Philadelphia, PA: Elsevier; 2019. 455–459 p.
5. D'Antò V, Bucci R, Franchi L, Rongo R, Michelotti A, Martina R. Class II functional orthopaedic treatment: A systematic review of systematic reviews. *Journal of Oral Rehabilitation*. 2015;42(8):624–42.
6. Ishaq RAR, Alhammadi MS, Fayed MMS, El-Ezz AA, Mostafa Y. Fixed functional appliances with multibracket appliances have no skeletal effect on the mandible: A systematic review and meta-analysis. *American Journal of Orthodontics and Dentofacial Orthopedics*. 2016;149(5):612–24.
7. Siara-Olds NJ, Pangrazio-Kulbersh V, Berger J, Bayirli B. Long-Term Dentoskeletal Changes with the Bionator, Herbst, Twin Block, and MARA Functional Appliances. *Angle Orthodontist*. 2010;80(1):18–29.

8. Weiland FJ, Ingervall B, Bantleon hans P, Droschl H. Initial effects of treatment of Class II malocclusion with the Herren activator, activator-headgear combination, and Jasper Jumper. *American Journal of Orthodontics and Dentofacial Orthopedics*. 1997;112(1):19–27.
9. Pancherz H. The Herbst appliance - Its biologic effects and clinical use. *American Journal of Orthodontics*. 1985;87(1):1-20.
10. Windmiller EC, Harrisburg M. The acrylic-splint Herbst appliance: A cephalometric evaluation. *American Journal of Orthodontics and Dentofacial Orthopedics*. 1993;104(1):73–84.
11. Paulsen HU. Orthodontic Treatment of the Class II Noncompliant patient. Papadopoulos MA, editor. Mosby; 2006. p. 35–7.
12. Insabralde NM, Rodrigues de Almeida M, Rodrigues de Almeida-Pedrin R, Flores-Mir C, Castanha Henriques JF. Retrospective comparison of dental and skeletal effects in the treatment of Class II malocclusion between Herbst and Xbow appliances. *American Journal of Orthodontics and Dentofacial Orthopedics*. 2021;160(4):544–51.
13. Pacha MM, Fleming PS, Pandis N, Shagmani M, Johal A. The use of the Hanks Herbst vs Twin-block in Class II malocclusion: A randomized controlled trial. *American Journal of Orthodontics and Dentofacial Orthopedics*. 2023;164(3):314–24.
14. Sangalli KL, Dutra-Horstmann KL, Correr GM, Topolski F, Flores-Mir C, Lagravère MO, Moro A. Three-dimensional skeletal and dentoalveolar sagittal and vertical changes associated with cantilever Herbst appliance in prepubertal patients with Class II malocclusion. *American Journal of Orthodontics and Dentofacial Orthopedics*. 2022;161(5):638-651.
15. Pancherz H. Treatment of Class II malocclusions by jumping the bite with the Herbst appliance A cephalometric investigation. *American Journal of Orthodontics*. 1979;76(4):423–42.
16. Pancherz H. The mechanism of Class II correction in Herbst appliance treatment: A cephalometric investigation. *American Journal of Orthodontics*. 1982;82(2):104–13.
17. Barnett GA, Higgins DW, Major PW, Flores-Mir C. Immediate skeletal and dentoalveolar effects of the crown or banded type Herbst Appliance on Class II division 1 malocclusion A Systematic Review. *Angle Orthodontist*. 2008;78(2):361-9.
18. Miller RA, Tieu L, Flores-Mir C. Incisor inclination changes produced by two compliance-free Class II correction protocols for the treatment of mild to moderate Class II malocclusions. *Angle Orthodontist*. 2013;83(3):431–6.

19. Higgins D. United States Patent. United States: United States Patent; US 6,168,430 B1, 2001. p. 1–9.
20. Flores-Mir C, Barnett G, Higgins DW, Heo G, Major PW. Short-term skeletal and dental effects of the Xbow appliance as measured on lateral cephalograms. *American Journal of Orthodontics and Dentofacial Orthopedics*. 2009;136(6):822–32.
21. Flores-Mir C, Witt MM, Heo G, Major PW. Analysis of anterior dentoalveolar and perioral aesthetic characteristics and their impact on the decision to undergo a Phase II orthodontic treatment. *European Journal of Orthodontics*. 2014;36:719-26.
22. Erbas B, Kocadereli I. Upper airway changes after Xbow appliance therapy evaluated with cone beam computed tomography. *Angle Orthodontist*. 2014;84(4):693–700.
23. Aziz T, Nassar U, Flores-Mir C. Prediction of lower incisor proclination during Xbow treatment based on initial cephalometric variables. *Angle Orthodontist*. 2011;0(0):1-8.
24. Flores-Mir C, Young A, Greiss A, Woynorowski M, Peng J. Lower incisor inclination changes during Xbow treatment according to vertical facial type. *Angle Orthodontist*. 2010 Nov;80(6):1075–80.
25. Tieu L, Normando D, Toogood R, Flores-Mir C. External apical root resorption generated by Forsus simultaneously with brackets vs. Xbow followed by brackets to correct Class II malocclusions. *Journal of the World Federation of Orthodontists*. 2015;4:120–3.
26. Flores-Mir C, McGrath L, Heo G, Major PW. Efficiency of molar distalization associated with second and third molar eruption stage: A systematic review. *Angle Orthodontist*. 2013;83(4):735-42.
27. Ehsani S, Nebbe B, Normando D, Lagravere MO, Flores-Mir C. Dental and skeletal changes in mild to moderate Class II malocclusions treated by either a Twin-block or Xbow appliance followed by full fixed orthodontic treatment. *Angle Orthodontist*. 2015;85(6):997–1002.
28. Arai Y, Tammisalo E, Iwai K, Hashimoto K, Shinoda K. Development of a compact computed tomographic apparatus for dental use. *Dentomaxillofacial Radiology*. 1999;28:245–8.
29. Fan Y, Schneider P, Matthews H, Roberts WE, Xu T, Wei R, Claes P, Clement J, Kilpatrick N, Penington A. 3D assessment of mandibular skeletal effects produced by the Herbst appliance. *BMC Oral Health*. 2020;20:2-9.
30. Cheib PL, Cevidanes LHS, Ruellas AC de O, Franchi L, Braga WFM, Oliveira D, Souki BQ. Displacement of the mandibular condyles immediately after Herbst appliance insertion - 3D assessment. *Turkish Journal of Orthodontics*. 2016;29(2):31–7.

31. Lecornu M, Cevidanes LHS, Zhu H, Wu C Da, Larson B, Nguyen T. Three-dimensional treatment outcomes in Class II patients treated with the Herbst appliance: A pilot study. *American Journal of Orthodontics and Dentofacial Orthopedics*. 2013;144(6):818–30.
32. Friede H. Normal development and growth of the human neurocranium and cranial base. *Scandinavian Journal of Plastic and Reconstructive Surgery*. 1981;15(3):163–9.
33. Lagravère MO, Major PW. Proposed reference point for 3-dimensional cephalometric analysis with cone-beam computerized tomography. *American Journal of Orthodontics and Dentofacial Orthopedics*. 2005;128(5):657–60.
34. Ling CP. Transverse, Vertical, and Antero-posterior changes between Tooth-borne versus Dresden Bone-borne Rapid Maxillary Expansion: A Randomized Controlled Clinical Trial [masters thesis]. Edmonton (AB): University of Alberta; 2016.
35. Nam HJ. Comparison of Skeletal and Dental Changes Obtained from a Tooth-Borne Maxillary Expansion Appliance Compared to the Damon System Assessed Through a Digital Volumetric Imaging [masters thesis]. Edmonton (AB): University of Alberta; 2019.
36. Portney L, Watkins M. *Foundations of Clinical Research : Applications to Practice*. Upper Saddle River, N.J.: Pearson/Prentice Hall; 2009. p.892–893.
37. Portney L. *Foundations of Clinical Research: Applications to Evidence-Based practice*. Fourth Ed. Philadelphia, PA: F. A. Davis Company; 2020. p. 473–4.
38. Papageorgiou S, Koretsi V, Jager A. Bias from historical control groups used in orthodontic research: a meta-epidemiological study. *European Journal of Orthodontics*. 2017;39(1):98-105.
39. Trivedi H, Tandon R, Singh K, Chandra P, Kulshrestha R, Gupta A, Ahmad I. Growth and Growth Studies in Orthodontics – A Review. *Journal of Dentistry and Oral Care*. 2016;2(2):65-69.
40. Pandis N, Fleming PS, Hopewell S, Altman DG. The CONSORT Statement: Application within and adaptations for orthodontic trials. *American Journal of Orthodontics and Dentofacial Orthopedics*. 2015;147(6):663–79.
41. Cozza P, Baccetti T, Franchi L, De Toffol L, McNamara JA. Mandibular changes produced by functional appliances in Class II malocclusion: A systematic review. 2006;129(5):1-12.
42. Ellis E, McNamara JA. Cephalometric evaluation of incisor position. *Angle Orthodontist*. 1986;56(4):324–44.

43. Burden DJ, McGuinness N, Stevenson M, McNamara T. Predictors of outcome among patients with Class II Division 1 malocclusion treated with fixed appliances in the permanent dentition. *American Journal of Orthodontics and Dentofacial Orthopedics*. 1999;116(4):452–9.
44. Aldajani T. Temporomandibular Joint Condylar/Fossa Positional Changes Post Herbst and Xbow Treatments in Adolescents Assessed Through CBCT Imaging [masters thesis]. Edmonton (AB): University of Alberta; 2022.
45. Jasper JJ, McNamara JA. The correction of interarch malocclusions using a fixed force module. *American Journal of Orthodontics and Dentofacial Orthopedics*. 1995;108(6):641-50.
46. Inchingolo AD, Ferrara I, Viapiano F, Netti A, Campanelli M, Buongiorno S, Latini G, Carpentiere V, Ciocia AM, Ceci S, Patano A, Piras F, Cardarelli F, Nemore D, Malcangi G, Noia, AD, Mancini A, Inchingolo AM, Marinelli G, Rapone B, Bordea IR, Scarano A, Lorusso F, Venere DD, Inchingolo F, Dipalma G. Rapid maxillary expansion on the adolescent patient: Systematic review and case report. *Children*. 2022;9:1-22.
47. de Almeida MR, Henriques JFC, de Almeida RR, Ursi W, McNamara JA. Short-term treatment effects produced by the Herbst appliance in the mixed dentition. *Angle Orthodontist*. 2005;75(4):540-7.

Chapter 4: Final Discussion

4.1 General Discussion and Summary of Findings

Neither the Xbow or the Herbst appliance cause increased mandibular dimensions of mandibular body length or ramus height that are clinically relevant. Minor skeletal changes in an anteroposterior direction occurred after use of the Herbst appliance. Overall, dental changes were similar for both the Herbst and Xbow groups including lower incisor proclination, lateral movement of molars due to incorporated expanders and distal tipping of maxillary molars. Additional retrusion and retroclination of maxillary incisors occurred in the Xbow group. In the Xbow group, the mandibular molars moved bodily anteriorly while the Herbst group had mesial crown tipping. Taken individually, the effect of each measurement's contribution to Class II correction is negligible, but cumulatively the effects of both the Xbow and Herbst contribute to Class II correction primarily through dental correction. With the differences between the Xbow and Herbst being so small, clinician preference will be the key factor for orthodontists' in choosing which appliance to use.

4.2 Study Limitations

Limitations are inherent to any study even when measures are taken to execute a high-quality study. In this study a total of 59 patients is not an ideal amount. Initially the plan was for 30 participants in each of the 3 experimental groups. Due to time constraints recruitment of participants ended after 59 patients. Randomized controlled trials are expensive, difficult to manage and orthodontic treatments take a considerable amount of time. Treating 59 patients for approximately a year is a huge accomplishment but failing to meet the originally planned 90 patients has its drawbacks. The main limitation encountered was during the statistical analysis. Due to the small sample size and the considerable number of overall variables, the dental and skeletal statistical analysis were run separately. To reduce the Type I error rate and prevent inflating false positive errors the α was divided by 2, so in essence an α of 0.025 was used for the Greenhouse-Geisser epsilon (ϵ) correction. This reduced the certainty of conclusions that can be drawn in particular with the skeletal anteroposterior changes, which there was only weak evidence of differences between T1 and T2. With the goal of Class II correctors to improve the anteroposterior relationship, including the skeletal relationship, it is unfortunate that only weak

evidence was found in the skeletal anteroposterior relationship. Overall, the conclusions that could be drawn from this study would be stronger if a larger sample size were used.

Another limitation for this study is that it does not investigate the stability of treatment. If Class II correction is achieved, but relapse occurs, and the overall result is lost then that treatment would not be useful clinically. This study neither investigated short-term or long-term stability. Since the T2 CBCT was taken immediately after removal of the Herbst and Xbow there was no time for relapse to occur. Additionally, when an appliance is removed patients may still posture forward when they bite which has potential to overstate the results of the Class II correction.

Including a control group that is treated in parallel with the same inclusion criteria is a hugely beneficial for a high-quality study, but an untreated control group is ideal. The purpose of the control group is to serve as a baseline for comparison which estimates what normal growth occurs in the growing population. This is a reference to compare the treatment effects of the Herbst and Xbow appliances to determine what changes were caused by growth and what changes were caused by appliance wear. An ideal control group for this study would have a CBCT taken and then after 12 months another CBCT with no orthodontic intervention. Our control group had full bonding of braces during the 12 months, which assisted in decreasing overall participation time for these patients with the disadvantage of no longer having a not orthodontically treated control group. Adding braces causes dental changes as the dental arches level and align. Treatment effects expected, in the control group with braces, include proclination of incisors as crowding resolves and broadening of both arches from archwire development. These dental changes must be considered when evaluating the dental changes attributed to appliance wear. To mitigate some of the effects, no interarch elastics or other force modalities were used in the control group to attempt to fix the patients' class II anteroposterior relationship during the duration of this study.

One final limitation noted involved the 3D plane created to compare the anteroposterior measurements. An ideal coronal plane would run perpendicular to the Frankfort Horizontal plane. By using the three landmarks of right/left infraorbital foramen and the nasopalatine

foramen to create a plane the result is not perpendicular to the Frankfort Horizontal plane (see figure 3). These landmarks were due to their ease of landmarking and that the infraorbital foramen is in the stable cranial base. The resulting plane, instead of being 90° to the Frankfort Horizontal plane, is at an obtuse angle. The angled plane results in a slightly decreased amount of the true anteroposterior movement being reported, but the reported amount would be consistent since all three treatment groups were measured off the angled plane.

4.3 Future Recommendations

Further research on this topic can include following these patients through Phase 2 of orthodontic treatment involving full bonding to complete comprehensive treatment. This would be beneficial as it can determine how using a Herbst or Xbow appliance effects patient outcomes. Additionally, this further research can determine if treatment using Herbst or Xbow treatment shortens overall treatment time which would offset the inconveniences and costs of using a fixed Class II corrector. Long term retention of results could be researched by following the patient outcomes not only after the end of comprehensive treatment but also several years following to determine if significant relapse occurs long term.

Further research should determine three landmarks to construct a coronal plane that is more perpendicular to the Frankfort Horizontal plane for anteroposterior measurements. Ideally these landmarks should not change due to patient growth, easily identifiable and located far apart from each other.

Not specific to this study, but in general, further orthodontic research should focus on randomized controlled trials. Randomized controlled trials if of high quality contribute can be clinically useful and provide context for evidence-based decision making by orthodontists. In the context of Class II correctors, more randomized controlled trials are needed to settle the controversies of acceleration of growth versus true stimulation of additional growth, or the opposing evidence stating that there are no skeletal changes from using Class II correctors.

Bibliography

1. Proffit WR, Fields HW, Larson BE, Sarver DM. Contemporary orthodontics. 6th ed. Philadelphia, PA: Elsevier; 2019. 2–10 p.
2. McNamara J. Components of class II malocclusion in children 8-10 years of age. *Angle Orthodontist*. 1981;51(3):177–202.
3. Lin F, Ren M, Yao L, He Y, Guo J, Ye Wenzhou Q. Psychosocial impact of dental esthetics regulates motivation to seek orthodontic treatment. *American Journal of Orthodontics and Dentofacial Orthopedics*. 2016;150(3):476-82.
4. Proffit WR, Fields HW, Larson BE, Sarver DM. Contemporary Orthodontics. 6th ed. Philadelphia, PA: Elsevier; 2019. 657–678 p.
5. Proffit WR, Fields HW, Larson BE, Sarver DM. Contemporary Orthodontics. 6th ed. Philadelphia, PA: Elsevier; 2019. 225–226 p.
6. Case CS. The question of extraction in orthodontia. *American Journal of Orthodontics and Dentofacial Orthopedics*. 1964;50(9):660–91.
7. Benson PE, Alshawy E, Fenton GD, Frawley T, Misra S, Ng T, O’Malley P, Smith G. Extraction vs nonextraction of premolars for orthodontic treatment: A scoping review examining the extent, range, and characteristics of the literature. *American Journal of Orthodontics and Dentofacial Orthopedics*. 2023;164(3):368–76.
8. Paik CH, Park IK, Woo YJ, Kim TW. Orthodontic Miniscrew Implant. Harradine N, editor. Mosby Ltd; 2009.
9. Proffit WR, Fields HW, Larson BE, Sarver DM. Contemporary Orthodontics. 6th ed. Philadelphia, PA: Elsevier; 2019. 455–459 p.
10. Baccetti T, Franchi L, Toth LR, McNamara JA. Treatment timing for Twin-block therapy. *American Journal of Orthodontics and Dentofacial Orthopedics*. 2000;118(2):159–70.
11. Great Lakes Dental Technologies [Internet]. Tonawanda, NY: [publisher unknown]; 2024. Higgins XBOW Class II Corrector. [cited 2024 Jan 14]. Available from: <https://www.greatlakesdentaltech.com/higgins-xbow-class-ii-corrector.html>
12. Xbow® [Internet]. [place unknown]: Crossbow® Orthodontic; 2024. About the Xbow® (Crossbow®) Class II Corrector. [cited 2023 Oct 23]. Available from: <https://crossboworthodontic.com/xbow-class-ii-corrector/>

13. Flores-Mir C, Barnett G, Higgins DW, Heo G, Major PW. Short-term skeletal and dental effects of the Xbow appliance as measured on lateral cephalograms. *American Journal of Orthodontics and Dentofacial Orthopedics*. 2009;136(6):822–32.
14. Flores-Mir C, Witt MM, Heo G, Major PW. Analysis of anterior dentoalveolar and perioral aesthetic characteristics and their impact on the decision to undergo a Phase II orthodontic treatment. *European Journal of Orthodontics*. 2014;36:719-26.
15. Erbas B, Kocadereli I. Upper airway changes after Xbow appliance therapy evaluated with cone beam computed tomography. *Angle Orthodontist*. 2014;84(4):693–700.
16. Aziz T, Nassar U, Flores-Mir C. Prediction of lower incisor proclination during Xbow treatment based on initial cephalometric variables. *Angle Orthodontist*. 2011;0(0):1-8.
17. Miller RA, Tieu L, Flores-Mir C. Incisor inclination changes produced by two compliance-free Class II correction protocols for the treatment of mild to moderate Class II malocclusions. *Angle Orthodontist*. 2013;83(3):431–6.
18. Flores-Mir C, Young A, Greiss A, Woynorowski M, Peng J. Lower incisor inclination changes during Xbow treatment according to vertical facial type. *Angle Orthodontist*. 2010 Nov;80(6):1075–80.
19. Insabralde NM, Rodrigues de Almeida M, Rodrigues de Almeida-Pedrin R, Flores-Mir C, Castanha Henriques JF. Retrospective comparison of dental and skeletal effects in the treatment of Class II malocclusion between Herbst and Xbow appliances. *American Journal of Orthodontics and Dentofacial Orthopedics*. 2021;160(4):544–51.
20. Tieu L, Normando D, Toogood R, Flores-Mir C. External apical root resorption generated by Forsus simultaneously with brackets vs. Xbow followed by brackets to correct Class II malocclusions. *Journal of the World Federation of Orthodontists*. 2015;4:120–3.
21. Flores-Mir C, McGrath L, Heo G, Major PW. Efficiency of molar distalization associated with second and third molar eruption stage: A systematic review. *Angle Orthodontist*. 2013;83(4):735-42.
22. Ehsani S, Nebbe B, Normando D, Lagravere MO, Flores-Mir C. Dental and skeletal changes in mild to moderate Class II malocclusions treated by either a Twin-block or Xbow appliance followed by full fixed orthodontic treatment. *Angle Orthodontist*. 2015;85(6):997–1002.
23. Pancherz H. The Herbst appliance - Its biologic effects and clinical use. *American Journal of Orthodontics*. 1985;87(1):1-20.

24. Windmiller EC, Harrisburg M. The acrylic-splint Herbst appliance: A cephalometric evaluation. *American Journal of Orthodontics and Dentofacial Orthopedics*. 1993;104(1):73–84.
25. Paulsen HU. Orthodontic Treatment of the Class II Noncompliant patient. Papadopoulos MA, editor. Mosby; 2006. p. 35–7.
26. Broadbent BH. A new X-ray technique and its application to orthodontia. *Angle Orthodontist*. 1931;1(2):45–66.
27. Baumrind S, Frantz RC. The reliability of head film measurements 1. Landmark identification. *American Journal of Orthodontics*. 1971;60(2):111–27.
28. Scarfe WC. Clinical recommendations regarding use of cone beam computed tomography in orthodontics. Position statement by the American Academy of Oral and Maxillofacial Radiology. *Oral Surg Oral Med Oral Pathol Oral Radiol*. 2013;116(2):238–57.
29. Arai Y, Tammisalo E, Iwai K, Hashimoto K, Shinoda K. Development of a compact computed tomographic apparatus for dental use. *Dentomaxillofacial Radiology*. 1999;28:245–8.
30. Scarfe WC, Azevedo B, Toghyani S, Farman AG. Cone Beam Computed Tomographic imaging in orthodontics. *Australian Dental Journal*. 2017;62(1):33–50.
31. Shukla S, Chug A, Afrashtehfar KI. Role of cone beam computed tomography in diagnosis and treatment planning in dentistry: An update. *Journal of International Society of Preventive and Community Dentistry*. 2017;7:125–36.
32. Benavides E, Krecioch JR, Connolly RT, Allareddy T, Buchanan A, Spelic D, O’Brien KK, Keels MA, Mascarenhas AK, Duong M, Aerne-Bowe MJ, Ziegler KM, Lipman RD. Optimizing radiation safety in dentistry Clinical recommendations and regulatory considerations. *The Journal of the American Dental Association*. 2024;155(4):280-293.
33. Sangalli KL, Dutra-Horstmann KL, Correr GM, Topolski F, Flores-Mir C, Lagravère MO, Moro A. Three-dimensional skeletal and dentoalveolar sagittal and vertical changes associated with cantilever Herbst appliance in prepubertal patients with Class II malocclusion. *American Journal of Orthodontics and Dentofacial Orthopedics*. 2022;161(5):638-651.
34. Fan Y, Schneider P, Matthews H, Roberts WE, Xu T, Wei R, Claes P, Clement J, Kilpatrick N, Penington A. 3D assessment of mandibular skeletal effects produced by the Herbst appliance. *BMC Oral Health*. 2020;20:2-9.

35. Cheib PL, Cevidanes LHS, Ruellas AC de O, Franchi L, Braga WFM, Oliveira D, Souki BQ. Displacement of the mandibular condyles immediately after Herbst appliance insertion - 3D assessment. *Turkish Journal of Orthodontics*. 2016;29(2):31–7.
36. Lecornu M, Cevidanes LHS, Zhu H, Wu C Da, Larson B, Nguyen T. Three-dimensional treatment outcomes in Class II patients treated with the Herbst appliance: A pilot study. *American Journal of Orthodontics and Dentofacial Orthopedics*. 2013;144(6):818–30.
37. Pandis N, Fleming PS, Hopewell S, Altman DG. The CONSORT Statement: Application within and adaptations for orthodontic trials. *American Journal of Orthodontics and Dentofacial Orthopedics*. 2015;147(6):663–79.
38. Millett DT, Benson PE, Cunningham SJ, McIntyre GT, Fleming PS, Naini FB, Tsihlaki A. Systematic reviews in orthodontics: A fresh look to promote renewal and reduce redundancy. *American Journal of Orthodontics and Dentofacial Orthopedics*. 2022;162:1–2.
39. Bishara SE. Class II malocclusions: Diagnostic and clinical considerations with and without treatment. *Seminars in Orthodontics*. 2006;12(1):11–24.
40. Proffit WR, Fields HW, Larson BE, Sarver DM. *Contemporary Orthodontics*. 6th ed. Philadelphia, PA: Elsevier; 2019.
41. McNamara JA, Peterson JE, Alexander RG. Three-dimensional diagnosis and management of Class II malocclusion in the mixed dentition. *Seminars in Orthodontics*. 1996;2(2):114–37.
42. McNamara J. Components of Class II malocclusion in children 8-10 years of age. *Angle Orthodontist*. 1981;51(3):177–202.
43. Illing HM, Morris DO, Lee RT. A prospective evaluation of Bass, Bionator and Twin Block appliances. Part I - the hard tissues. *European Journal of Orthodontics*. 1998;20:501–16.
44. Clark WJ. The twin block technique A functional orthopedic appliance system. 1988;93(1):1-18.
45. Weiland FJ, Ingervall B, Bantleon hans P, Droschl H. Initial effects of treatment of Class II malocclusion with the Herren activator, activator-headgear combination, and Jasper Jumper. *American Journal of Orthodontics and Dentofacial Orthopedics*. 1997;112(1):19–27.
46. Kim-Berman H, McNamara JA, Lints JP, McMullen C, Franchi L. Treatment effects of the Carriere Motion 3D appliance for the correction of Class II malocclusion in adolescents. *Angle Orthodontist*. 2019;89(6):839–46.
47. Ucem TT, Okay C, Gulsen A. Effects of a three-dimensional bimetric maxillary distalizing arch. *European Journal of Orthodontics*. 2000;22:293–8.

48. Ramon Pujols SC, Nogueira CQ, Reis RS, Fonçatti CF, Castanha Henriques JF, Janson G. Stability of Class II malocclusion treatment with the distal jet followed by fixed appliances. *American Journal of Orthodontics and Dentofacial Orthopedics*. 2020;158(3):363–70.
49. Cozza P, Baccetti T, Franchi L, De Toffol L, Mcnamara JA. Mandibular changes produced by functional appliances in Class II malocclusion: A systematic review. 2006;129(5):1-12.
50. D'Antò V, Bucci R, Franchi L, Rongo R, Michelotti A, Martina R. Class II functional orthopaedic treatment: A systematic review of systematic reviews. *Journal of Oral Rehabilitation*. 2015;42(8):624–42.
51. Ishaq RAR, Alhammadi MS, Fayed MMS, El-Ezz AA, Mostafa Y. Fixed functional appliances with multibracket appliances have no skeletal effect on the mandible: A systematic review and meta-analysis. *American Journal of Orthodontics and Dentofacial Orthopedics*. 2016;149(5):612–24.
52. Siara-Olds NJ, Pangrazio-Kulbersh V, Berger J, Bayirli B. Long-Term Dentoskeletal Changes with the Bionator, Herbst, Twin Block, and MARA Functional Appliances. *Angle Orthodontist*. 2010;80(1):18–29.
53. Miller RA, Tieu L, Flores-Mir C. Incisor inclination changes produced by two compliance-free Class II correction protocols for the treatment of mild to moderate Class II malocclusions. *Angle Orthodontist*. 2013;83(3):431–6.
54. Franchi L, Baccetti T. Prediction of Individual Mandibular Changes Induced by Functional Jaw Orthopedics Followed by Fixed Appliances in Class II Patients. *Angle Orthodontist*. 2006;76(6):950-4.
55. Camilla Tulloch JF, Phillips C, Koch G, Proffit WR, Hill C, Carolina N. The effect of early intervention on skeletal pattern in Class II malocclusion: A randomized clinical trial. *American Journal of Orthodontics and Dentofacial Orthopedics*. 1997;111(4):391–400.
56. Pancherz H. The Herbst appliance - Its biologic effects and clinical use. *American Journal of Orthodontics*. 1985;87(1):1-20.
57. Windmiller EC, Harrisburg M. The acrylic-splint Herbst appliance: A cephalometric evaluation. *American Journal of Orthodontics and Dentofacial Orthopedics*. 1993;104(1):73–84.
58. Pacha MM, Fleming PS, Pandis N, Shagmani M, Johal A. The use of the Hanks Herbst vs Twin-block in Class II malocclusion: A randomized controlled trial. *American Journal of Orthodontics and Dentofacial Orthopedics*. 2023;164(3):314–24.

59. Paulsen HU. Orthodontic Treatment of the Class II Noncompliant patient. Papadopoulos MA, editor. Mosby; 2006. p. 35–7.
60. Insabralde NM, Rodrigues de Almeida M, Rodrigues de Almeida-Pedrin R, Flores-Mir C, Castanha Henriques JF. Retrospective comparison of dental and skeletal effects in the treatment of Class II malocclusion between Herbst and Xbow appliances. *American Journal of Orthodontics and Dentofacial Orthopedics*. 2021;160(4):544–51.
61. Barnett GA, Higgins DW, Major PW, Flores-Mir C. Immediate skeletal and dentoalveolar effects of the crown or banded type Herbst Appliance on Class II division 1 malocclusion A Systematic Review. *Angle Orthodontist*. 2008;78(2):361-9.
62. Sangalli KL, Dutra-Horstmann KL, Correr GM, Topolski F, Flores-Mir C, Lagravère MO, Moro A. Three-dimensional skeletal and dentoalveolar sagittal and vertical changes associated with cantilever Herbst appliance in prepubertal patients with Class II malocclusion. *American Journal of Orthodontics and Dentofacial Orthopedics*. 2022;161(5):638-651.
63. de Almeida MR, Henriques JFC, de Almeida RR, Ursi W, Mcnamara JA. Short-term treatment effects produced by the Herbst appliance in the mixed dentition. *Angle Orthodontist*. 2005;75(4):540-7.
64. Pancherz H. The mechanism of Class II correction in Herbst appliance treatment: A cephalometric investigation. *American Journal of Orthodontics*. 1982;82(2):104–13.
65. Pancherz H. Treatment of Class II malocclusions by jumping the bite with the Herbst appliance A cephalometric investigation. *American Journal of Orthodontics*. 1979;76(4):423–42.
66. Higgins D. United States Patent. United States: United States Patent; US 6,168,430 B1, 2001. p. 1–9.
67. Flores-Mir C, Barnett G, Higgins DW, Heo G, Major PW. Short-term skeletal and dental effects of the Xbow appliance as measured on lateral cephalograms. *American Journal of Orthodontics and Dentofacial Orthopedics*. 2009;136(6):822–32.
68. Great Lakes Dental Technologies [Internet]. Tonawanda, NY: [publisher unknown]; 2024. Higgins XBOW Class II Corrector. [cited 2024 Jan 14]. Available from: <https://www.greatlakesdentaltech.com/higgins-xbow-class-ii-corrector.html>
69. Xbow® [Internet]. [place unknown]: Crossbow® Orthodontic; 2024. About the Xbow® (Crossbow®) Class II Corrector. [cited 2023 Oct 23]. Available from: <https://crossboworthodontic.com/xbow-class-ii-corrector/>

70. Ehsani S, Nebbe B, Normando D, Lagravere MO, Flores-Mir C. Dental and skeletal changes in mild to moderate Class II malocclusions treated by either a Twin-block or Xbow appliance followed by full fixed orthodontic treatment. *Angle Orthodontist*. 2015;85(6):997–1002.
71. Flores-Mir C, McGrath LM, Heo G, Major PW. Efficiency of molar distalization with the XBow appliance related to second molar eruption stage. *European Journal of Orthodontics*. 2013;35(6):745–51.
72. Flores-Mir C, Young A, Greiss A, Woynorowski M, Peng J. Lower incisor inclination changes during Xbow treatment according to vertical facial type. *Angle Orthodontist*. 2010;80(6):1075–80.
73. Tieu LD, Saltaji H, Normando D, Flores-Mir C. Radiologically determined orthodontically induced external apical root resorption in incisors after non-surgical orthodontic treatment of class II division 1 malocclusion: a systematic review. *Progress in Orthodontics*. 2014;15:48.
74. Tieu L, Normando D, Toogood R, Flores-Mir C. External apical root resorption generated by Forsus simultaneously with brackets vs. Xbow followed by brackets to correct Class II malocclusions. *Journal of the World Federation of Orthodontists*. 2015;4:120–3.
75. Broadbent BH. A new X-ray technique and its application to orthodontia. *Angle Orthodontist*. 1931;1(2):45–66.
76. Ricketts RM. Perspectives in the clinical application of cephalometrics: The first fifty years. *Angle Orthodontist*. 1981;51(2):115–50.
77. Chien PC, Parks ET, Eraso F, Hartsfield JK, Roberts WE, Ofner S. Comparison of reliability in anatomical landmark identification using two-dimensional digital cephalometrics and three-dimensional cone beam computed tomography in vivo. *Dentomaxillofacial Radiology*, 2009;38(5):262–73.
78. H Dibbets JM, Nolte K, Marburg D. Effect of magnification on lateral cephalometric studies. 2002;122(2):196-201.
79. Baumrind S, Frantz RC. The reliability of head film measurements 1. Landmark identification. *American Journal of Orthodontics*. 1971;60(2):111–27.
80. Zaman MU. Comparing radiation doses in CBCT and medical CT imaging for dental applications. *Journal of Pharmacy and Bioallied Sciences*. 2024;16(1):883–5.
81. White SC. Cone-beam imaging in dentistry. *Health Physics*. 2008;95(5):628–37.

82. Scarfe WC, Angelopoulos C. Maxillofacial Cone Beam Computed Tomography: Principles, Techniques and Clinical Applications. New York City (NY): Springer; 2018. p. 13-41.
83. Scarfe WC. Clinical recommendations regarding use of cone beam computed tomography in orthodontics. Position statement by the American Academy of Oral and Maxillofacial Radiology. *Oral Surg Oral Med Oral Pathol Oral Radiol.* 2013;116(2):238–57.
84. Benavides E, Krecioch JR, Connolly RT, Allareddy T, Buchanan A, Spelic D, O'Brien KK, Keels MA, Mascarenhas AK, Duong M, Aerne-Bowe MJ, Ziegler KM, Lipman RD. Optimizing radiation safety in dentistry Clinical recommendations and regulatory considerations. *The Journal of the American Dental Association.* 2024;155(4):280-293.
85. Siegel JA, Pennington CW, Sacks B. Subjecting radiologic imaging to the linear no-threshold hypothesis: A non sequitur of non-trivial proportion. *The Journal of Nuclear Medicine.* 2017;58:1–6.
86. Fan Y, Schneider P, Matthews H, Roberts WE, Xu T, Wei R, Claes P, Clement J, Kilpatrick N, Penington A. 3D assessment of mandibular skeletal effects produced by the Herbst appliance. *BMC Oral Health.* 2020;20:2-9.
87. Cheib PL, Cevidanes LHS, Ruellas AC de O, Franchi L, Braga WFM, Oliveira D, Souki BQ. Displacement of the mandibular condyles immediately after Herbst appliance insertion - 3D assessment. *Turkish Journal of Orthodontics.* 2016;29(2):31–7.
88. Lecornu M, Cevidanes LHS, Zhu H, Wu C Da, Larson B, Nguyen T. Three-dimensional treatment outcomes in Class II patients treated with the Herbst appliance: A pilot study. *American Journal of Orthodontics and Dentofacial Orthopedics.* 2013;144(6):818–30.
89. Cevidanes LHS, Styner MA, Proffit WR. Image analysis and superimposition of 3-dimensional cone-beam computed tomography models. *American Journal of Orthodontics and Dentofacial Orthopedics.* 2006;129(5):611–8.
90. Cevidanes LHC, Heymann G, Cornelis MA, DeClerck HJ, Tulloch JFC. Superimposition of 3-dimensional cone-beam computed tomography models of growing patients. *American Journal of Orthodontics and Dentofacial Orthopedics.* 2009;136(1):94–9.
91. Lagravère MO, Hansen L, Harzer W, Major PW. Plane orientation for standardization in 3-dimensional cephalometric analysis with computerized tomography imaging. *American Journal of Orthodontics and Dentofacial Orthopedics.* 2006;129(5):601–4.

92. Ghoneima A, Cho H, Farouk K, Kula K. Accuracy and reliability of landmark-based, surface-based and voxel-based 3D cone-beam computed tomography superimposition methods. *Orthodontics & Craniofacial Research*. 2017;20:227–36.
93. Ponce-Garcia C, Ruellas ACDO, Cevidanes LHS, Flores-Mir C, Carey JP, Lagravere-Vich M. Measurement error and reliability of three available 3D superimposition methods in growing patients. *Head & Face Medicine*. 2020;16:1-20.
94. Pinsky HM, Dyda S, Pinsky RW, Misch KA, Sarment D. Accuracy of three-dimensional measurements using cone-beam CT. *Dentomaxillofacial Radiology*. 2006;35:410–6.
95. Shibata M, Nawa H, Kise Y, Fuyamada M, Yoshida K, Katsumata A, Arijji E, Goto S. Reproducibility of three-dimensional coordinate systems based on craniofacial landmarks A tentative evaluation of four systems created on images obtained by cone-beam computed tomography with a large field of view. *Angle Orthodontist*. 2012;82(5):776-784.
96. McNamara JA, Peterson JE, Alexander RG. Three-dimensional diagnosis and management of Class II malocclusion in the mixed dentition. *Seminars in Orthodontics*. 1996;2(2):114–37.
97. Proffit WR, Fields HW, Larson BE, Sarver DM. *Contemporary Orthodontics*. 6th ed. Philadelphia, PA: Elsevier; 2019.
98. Bishara SE. Class II malocclusions: Diagnostic and clinical considerations with and without treatment. *Seminars in Orthodontics*. 2006;12(1):11–24.
99. Proffit WR, Fields HW, Larson BE, Sarver DM. *Contemporary Orthodontics*. 6th ed. Philadelphia, PA: Elsevier; 2019. 455–459 p.
100. D’Antò V, Bucci R, Franchi L, Rongo R, Michelotti A, Martina R. Class II functional orthopaedic treatment: A systematic review of systematic reviews. *Journal of Oral Rehabilitation*. 2015;42(8):624–42.
101. Ishaq RAR, Alhammadi MS, Fayed MMS, El-Ezz AA, Mostafa Y. Fixed functional appliances with multibracket appliances have no skeletal effect on the mandible: A systematic review and meta-analysis. *American Journal of Orthodontics and Dentofacial Orthopedics*. 2016;149(5):612–24.
102. Siara-Olds NJ, Pangrazio-Kulbersh V, Berger J, Bayirli B. Long-Term Dentoskeletal Changes with the Bionator, Herbst, Twin Block, and MARA Functional Appliances. *Angle Orthodontist*. 2010;80(1):18–29.

103. Weiland FJ, Ingervall B, Bantleon hans P, Droschl H. Initial effects of treatment of Class II malocclusion with the Herren activator, activator-headgear combination, and Jasper Jumper. *American Journal of Orthodontics and Dentofacial Orthopedics*. 1997;112(1):19–27.
104. Pancherz H. The Herbst appliance - Its biologic effects and clinical use. *American Journal of Orthodontics*. 1985;87(1):1-20.
105. Windmiller EC, Harrisburg M. The acrylic-splint Herbst appliance: A cephalometric evaluation. *American Journal of Orthodontics and Dentofacial Orthopedics*. 1993;104(1):73–84.
106. Paulsen HU. Orthodontic Treatment of the Class II Noncompliant patient. Papadopoulos MA, editor. Mosby; 2006. p. 35–7.
107. Insabralde NM, Rodrigues de Almeida M, Rodrigues de Almeida-Pedrin R, Flores-Mir C, Castanha Henriques JF. Retrospective comparison of dental and skeletal effects in the treatment of Class II malocclusion between Herbst and Xbow appliances. *American Journal of Orthodontics and Dentofacial Orthopedics*. 2021;160(4):544–51.
108. Pacha MM, Fleming PS, Pandis N, Shagmani M, Johal A. The use of the Hanks Herbst vs Twin-block in Class II malocclusion: A randomized controlled trial. *American Journal of Orthodontics and Dentofacial Orthopedics*. 2023;164(3):314–24.
109. Sangalli KL, Dutra-Horstmann KL, Correr GM, Topolski F, Flores-Mir C, Lagravère MO, Moro A. Three-dimensional skeletal and dentoalveolar sagittal and vertical changes associated with cantilever Herbst appliance in prepubertal patients with Class II malocclusion. *American Journal of Orthodontics and Dentofacial Orthopedics*. 2022;161(5):638-651.
110. Pancherz H. Treatment of Class II malocclusions by jumping the bite with the Herbst appliance A cephalometric investigation. *American Journal of Orthodontics*. 1979;76(4):423–42.
111. Pancherz H. The mechanism of Class II correction in Herbst appliance treatment: A cephalometric investigation. *American Journal of Orthodontics*. 1982;82(2):104–13.
112. Barnett GA, Higgins DW, Major PW, Flores-Mir C. Immediate skeletal and dentoalveolar effects of the crown or banded type Herbst Appliance on Class II division 1 malocclusion A Systematic Review. *Angle Orthodontist*. 2008;78(2):361-9.
113. Miller RA, Tieu L, Flores-Mir C. Incisor inclination changes produced by two compliance-free Class II correction protocols for the treatment of mild to moderate Class II malocclusions. *Angle Orthodontist*. 2013;83(3):431–6.

114. Higgins D. United States Patent. United States: United States Patent; US 6,168,430 B1, 2001. p. 1–9.
115. Flores-Mir C, Barnett G, Higgins DW, Heo G, Major PW. Short-term skeletal and dental effects of the Xbow appliance as measured on lateral cephalograms. *American Journal of Orthodontics and Dentofacial Orthopedics*. 2009;136(6):822–32.
116. Flores-Mir C, Witt MM, Heo G, Major PW. Analysis of anterior dentoalveolar and perioral aesthetic characteristics and their impact on the decision to undergo a Phase II orthodontic treatment. *European Journal of Orthodontics*. 2014;36:719-26.
117. Erbas B, Kocadereli I. Upper airway changes after Xbow appliance therapy evaluated with cone beam computed tomography. *Angle Orthodontist*. 2014;84(4):693–700.
118. Aziz T, Nassar U, Flores-Mir C. Prediction of lower incisor proclination during Xbow treatment based on initial cephalometric variables. *Angle Orthodontist*. 2011;0(0):1-8.
119. Flores-Mir C, Young A, Greiss A, Woynorowski M, Peng J. Lower incisor inclination changes during Xbow treatment according to vertical facial type. *Angle Orthodontist*. 2010 Nov;80(6):1075–80.
120. Tieu L, Normando D, Toogood R, Flores-Mir C. External apical root resorption generated by Forsus simultaneously with brackets vs. Xbow followed by brackets to correct Class II malocclusions. *Journal of the World Federation of Orthodontists*. 2015;4:120–3.
121. Flores-Mir C, McGrath L, Heo G, Major PW. Efficiency of molar distalization associated with second and third molar eruption stage: A systematic review. *Angle Orthodontist*. 2013;83(4):735-42.
122. Ehsani S, Nebbe B, Normando D, Lagravere MO, Flores-Mir C. Dental and skeletal changes in mild to moderate Class II malocclusions treated by either a Twin-block or Xbow appliance followed by full fixed orthodontic treatment. *Angle Orthodontist*. 2015;85(6):997–1002.
123. Arai Y, Tammisalo E, Iwai K, Hashimoto K, Shinoda K. Development of a compact computed tomographic apparatus for dental use. *Dentomaxillofacial Radiology*. 1999;28:245–8.
124. Fan Y, Schneider P, Matthews H, Roberts WE, Xu T, Wei R, Claes P, Clement J, Kilpatrick N, Penington A. 3D assessment of mandibular skeletal effects produced by the Herbst appliance. *BMC Oral Health*. 2020;20:2-9.
125. Cheib PL, Cevidanes LHS, Ruellas AC de O, Franchi L, Braga WFM, Oliveira D, Souki BQ. Displacement of the mandibular condyles immediately after Herbst appliance insertion - 3D assessment. *Turkish Journal of Orthodontics*. 2016;29(2):31–7.

126. Lecornu M, Cevidanes LHS, Zhu H, Wu C Da, Larson B, Nguyen T. Three-dimensional treatment outcomes in Class II patients treated with the Herbst appliance: A pilot study. *American Journal of Orthodontics and Dentofacial Orthopedics*. 2013;144(6):818–30.
127. Friede H. Normal development and growth of the human neurocranium and cranial base. *Scandinavian Journal of Plastic and Reconstructive Surgery*. 1981;15(3):163–9.
128. Lagravère MO, Major PW. Proposed reference point for 3-dimensional cephalometric analysis with cone-beam computerized tomography. *American Journal of Orthodontics and Dentofacial Orthopedics*. 2005;128(5):657–60.
129. Ling CP. Transverse, Vertical, and Antero-posterior changes between Tooth-borne versus Dresden Bone-borne Rapid Maxillary Expansion: A Randomized Controlled Clinical Trial [masters thesis]. Edmonton (AB): University of Alberta; 2016.
130. Nam HJ. Comparison of Skeletal and Dental Changes Obtained from a Tooth-Borne Maxillary Expansion Appliance Compared to the Damon System Assessed Through a Digital Volumetric Imaging [masters thesis]. Edmonton (AB): University of Alberta; 2019.
131. Portney L, Watkins M. *Foundations of Clinical Research : Applications to Practice*. Upper Saddle River, N.J.: Pearson/Prentice Hall; 2009. p.892–893.
132. Portney L. *Foundations of Clinical Research: Applications to Evidence-Based practice*. Fourth Ed. Philadelphia, PA: F. A. Davis Company; 2020. p. 473–4.
133. Pandis N, Fleming PS, Hopewell S, Altman DG. The CONSORT Statement: Application within and adaptations for orthodontic trials. *American Journal of Orthodontics and Dentofacial Orthopedics*. 2015;147(6):663–79.
134. Cozza P, Baccetti T, Franchi L, De Toffol L, McNamara JA. Mandibular changes produced by functional appliances in Class II malocclusion: A systematic review. 2006;129(5):1-12.
135. Ellis E, McNamara JA. Cephalometric evaluation of incisor position. *Angle Orthodontist*. 1986;56(4):324–44.
136. Burden DJ, McGuinness N, Stevenson M, McNamara T. Predictors of outcome among patients with Class II Division 1 malocclusion treated with fixed appliances in the permanent dentition. *American Journal of Orthodontics and Dentofacial Orthopedics*. 1999;116(4):452–9.
137. Jasper JJ, McNamara JA. The correction of interarch malocclusions using a fixed force module. *American Journal of Orthodontics and Dentofacial Orthopedics*. 1995;108(6):641-50.

138. Inchingolo AD, Ferrara I, Viapiano F, Netti A, Campanelli M, Buongiorno S, Latini G, Carpentiere V, Ciocia AM, Ceci S, Patano A, Piras F, Cardarelli F, Nemore D, Malcangi G, Noia, AD, Mancini A, Inchingolo AM, Marinelli G, Rapone B, Bordea IR, Scarano A, Lorusso F, Venere DD, Inchingolo F, Dipalma G. Rapid maxillary expansion on the adolescent patient: Systematic review and case report. *Children*. 2022;9:1-22.
139. de Almeida MR, Henriques JFC, de Almeida RR, Ursi W, Mcnamara JA. Short-term treatment effects produced by the Herbst appliance in the mixed dentition. *Angle Orthodontist*. 2005;75(4):540-7.
140. Papageorgiou S, Koretsi V, Jager A. Bias from historical control groups used in orthodontic research: a meta-epidemiological study. *European Journal of Orthodontics*. 2017;39(1):98-105.
141. Trivedi H, Tandon R, Singh K, Chandra P, Kulshrestha R, Gupta A, Ahmad I. Growth and Growth Studies in Orthodontics – A Review. *Journal of Dentistry and Oral Care*. 2016;2(2):65-69.
142. Aldajani T. Temporomandibular Joint Condylar/Fossa Positional Changes Post Herbst and Xbow Treatments in Adolescents Assessed Through CBCT Imaging [masters thesis]. Edmonton (AB): University of Alberta; 2022.

Appendix

Table 10. Assumption testing for one-way MANOVA at T1

Assumptions tested for in MANOVA include:

1. Independence
2. Multivariate normality
3. Equal variance-covariance matrices (Box's M-test)
4. Linearity of all pairs of response variables

Based on the study design we can conclude there is independence and no confounding relationships between the subjects in the study or between treatment groups.

Normality of the data was assessed by inspection of boxplots. The following landmarks were not normally distributed and contained extreme univariate outliers (Figure 4 in appendix):

- Sagittal: 9, 21
- AP: 11, 16
- Axial: 6, 8, 12, 19, 21, 23, 26, 27, 30

To investigate if the extreme outliers affected the one-way MANOVA result, the test was run both including and excluding the outliers. When extreme outliers removed p value of 0.837 indicates the differences between the groups was not statistically significant. Since this was the same result as when outliers were included, the decision was made to include the outliers (Table 11 in appendix).

Mahalanobis distance was used to determine if data contained multivariate outliers. Due to large number of variables, Mahalanobis distance was calculated in 4 separate groups: Sagittal, Anteroposterior, Axial, Mandibular Dimensions with IMPA. Participant 12 was a multivariate outlier in both the Anteroposterior (p value 0.0007) and Axial (p value 0.0005) directions with p value > 0.001. To determine if the presence of outliers affected the on-way MANOVA, it was run both including and excluding participant 12. When outlier removed p value of 0.374 for Anteroposterior and p value of 0.539 for Axial indicates the differences between the groups were not statistically significant. Since this was the same result as when outliers were included, the decision was made to include participant 12 (Table 11 in appendix).

Due to large number of variables (25 Sagittal, 25 Anteroposterior, 26 Axial, 5 Mandibular Dimensions with IMPA) equal variance-covariance matrices were computed in subsections of skeletal sagittal, skeletal anteroposterior, skeletal axial, dental sagittal, dental anteroposterior, and dental axial as SPSS was unable to compute including all simultaneously. There was homogeneity of variance-covariance matrices, as assessed by Box's test of equality of covariance matrices with p values greater than 0.001 for each variable other than axial dental (Table 12 in appendix).

There were generally linear relationships between variables as assessed by scatterplot (Figure 5 in appendix).

Table 11. Assumption testing for one-way MANOVA for T2-T1

Normality of the data was assessed by inspection of boxplots. The following landmarks were not normally distributed and contained extreme univariate outliers (Figure 6 in appendix):

- Sagittal: 8, 12, 13, 14, 16, 20, 28, 31
- AP: 6, 14, 15, 32
- Axial: 24, 28
- Mandible Length

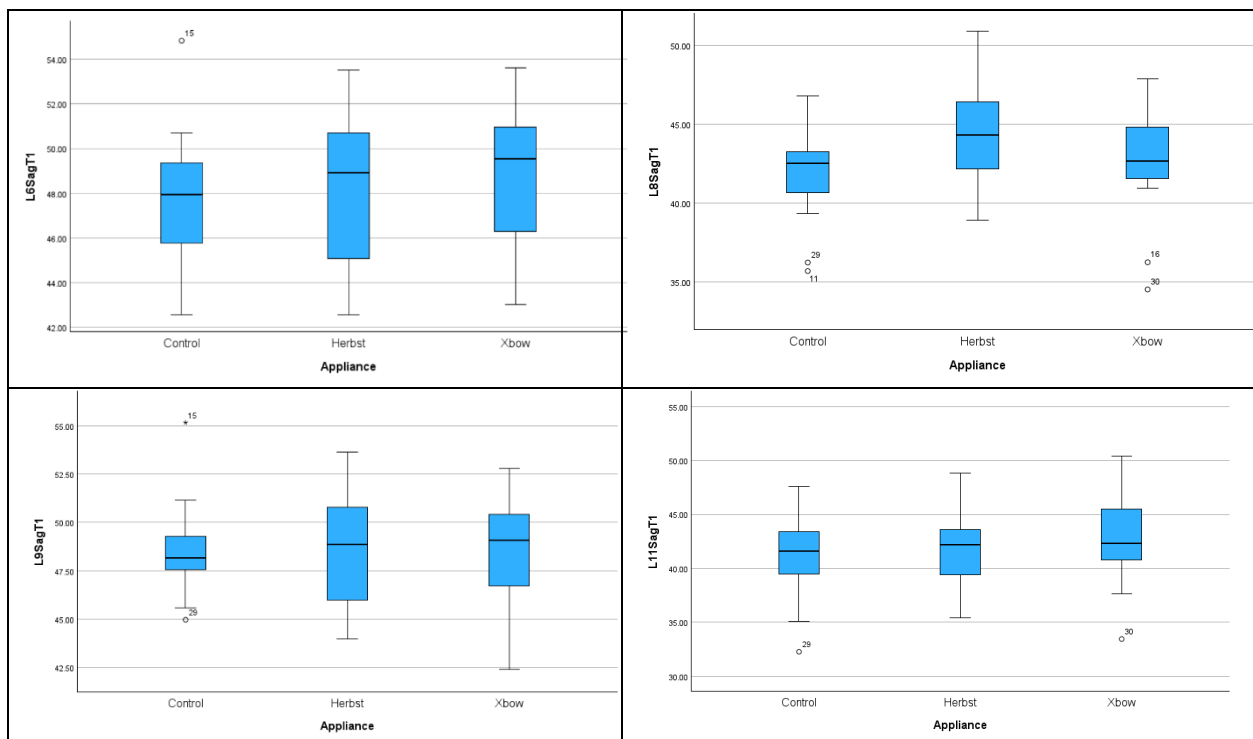
When extreme outliers removed p value of <0.001 indicates there are statistically significant differences between the groups (Table 13 in appendix). Since this was the same result as when outliers were included, the decision was made to include the outliers (Table 13 in appendix).

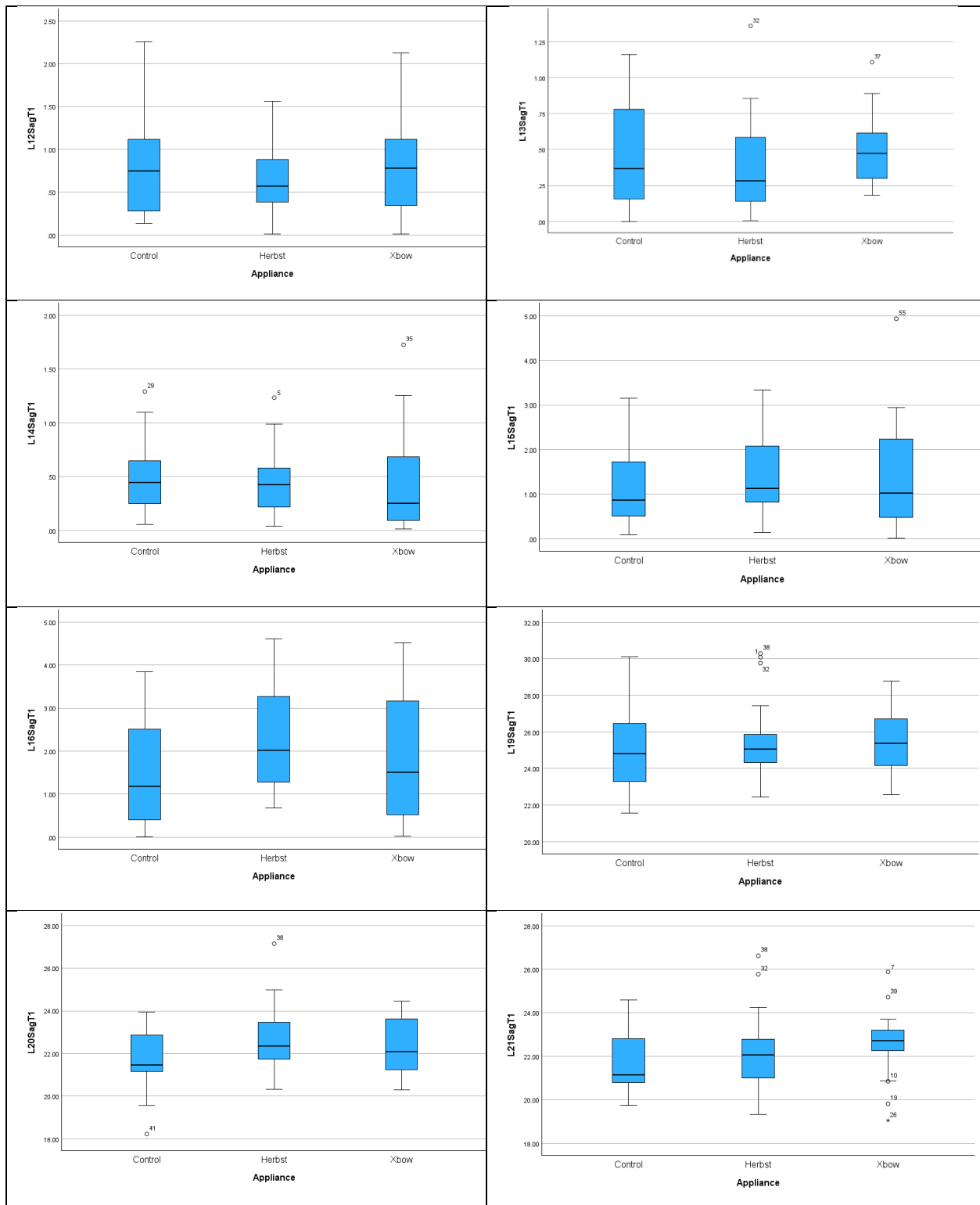
Mahalanobis distance was used to determine if data contained multivariate outliers. In the Sagittal direction participant 3 was a multivariate outlier (p value 0.0009). Participant 12 was a multivariate outlier in both the Anteroposterior (p value 0.0002) and Axial (p value 0.00009). In the Jaw Dimensions and IMPA group participant 57 was a multivariate outlier (p value 0.0004). These multivariate outliers have p values < 0.001 . When outliers removed all four p values <0.001 so statistically significant differences between the groups were seen (Table 13 in appendix). This was consistent with the result when outliers were included, the decision was made to include multivariate outliers (Table 13 in appendix).

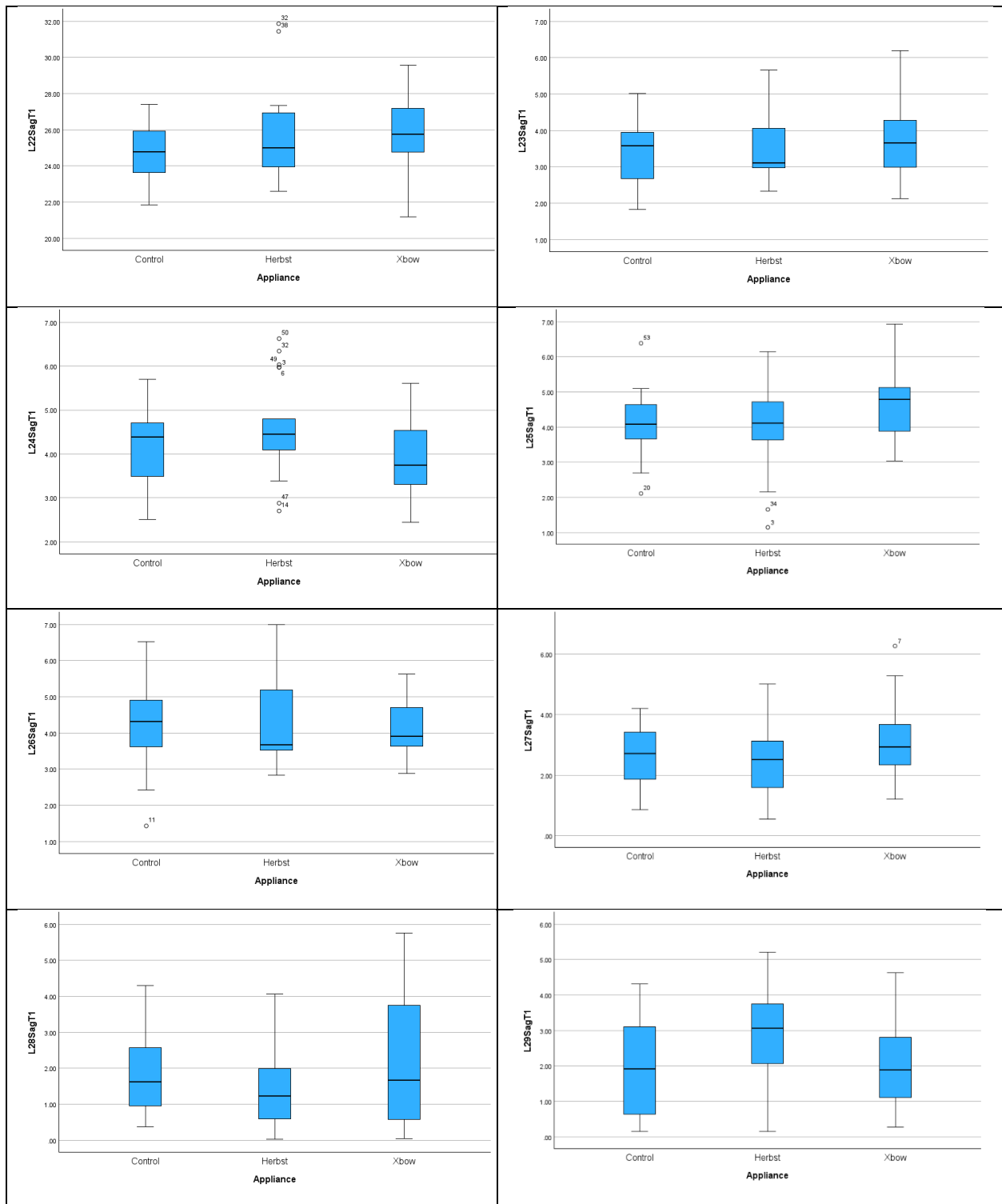
Due to large number of variables (15 Sagittal, 15 Anteroposterior, 16 Axial, 3 Mandibular Dimensions with IMPA) equal variance-covariance matrices were computed in subsections of skeletal sagittal, skeletal anteroposterior, skeletal axial, dental sagittal, dental anteroposterior, and dental axial as SPSS was unable to compute including all at the same time. There was homogeneity of variance-covariance matrices, as assessed by Box's test of equality of covariance matrices with p values greater than 0.001 for each of the three skeletal groupings (Table 14 in appendix). The three dental groupings did not have homogeneity of variance-covariance matrices with p values of <0.001 (Table 14 in appendix).

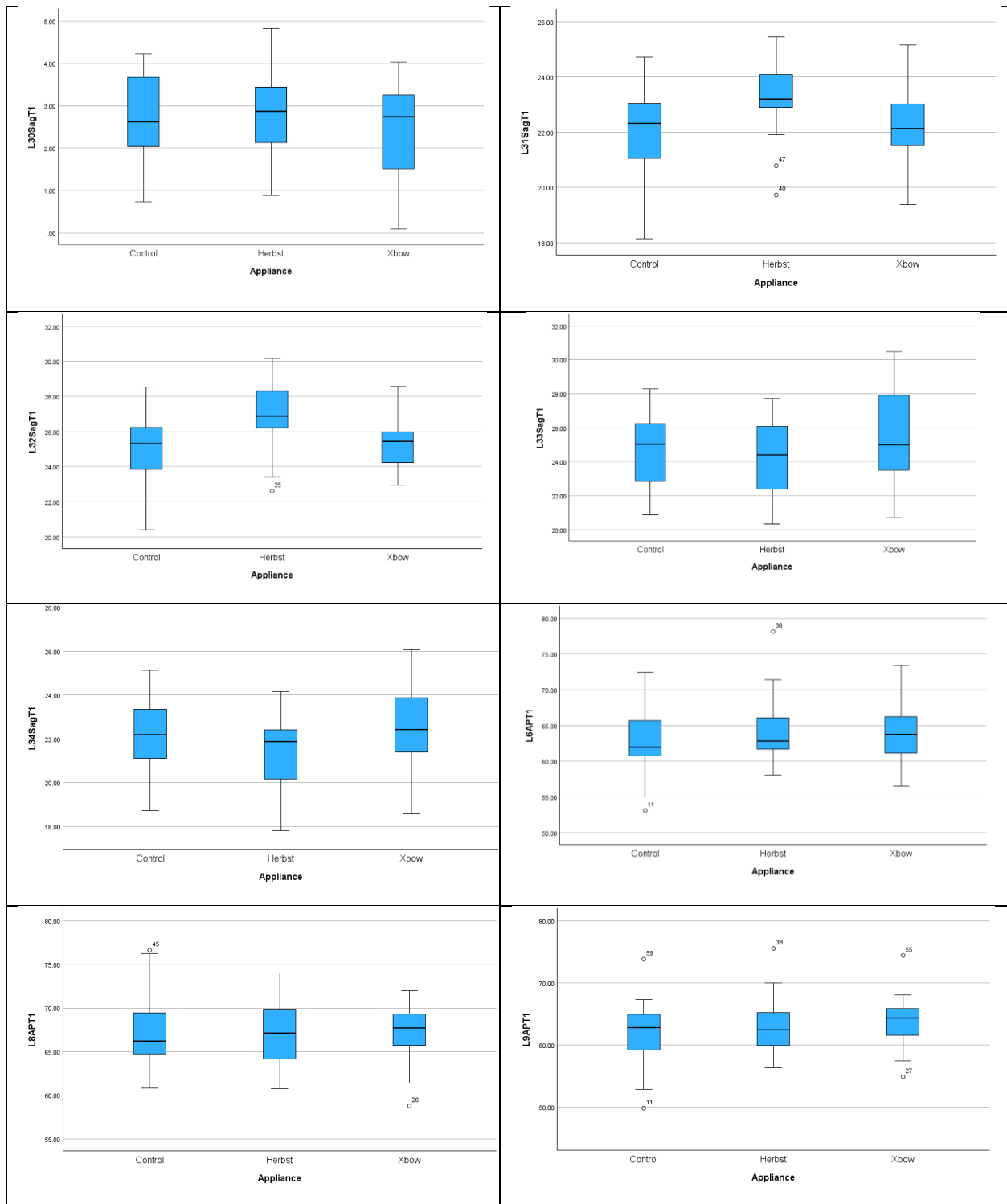
There were generally linear relationships between variables as assessed by scatterplot (Figure 7 in appendix).

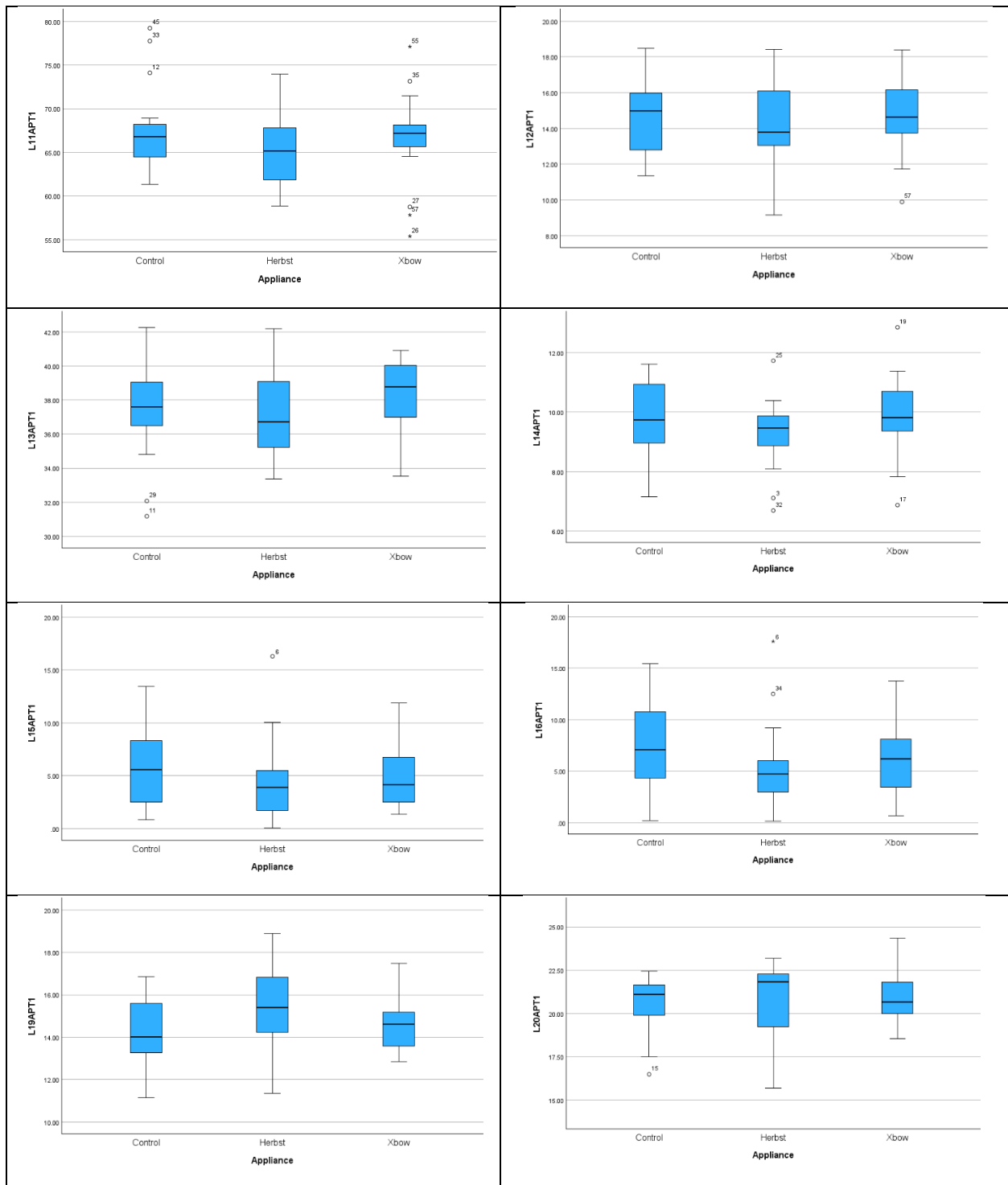
Figure 4. Boxplots for MANOVA at T1

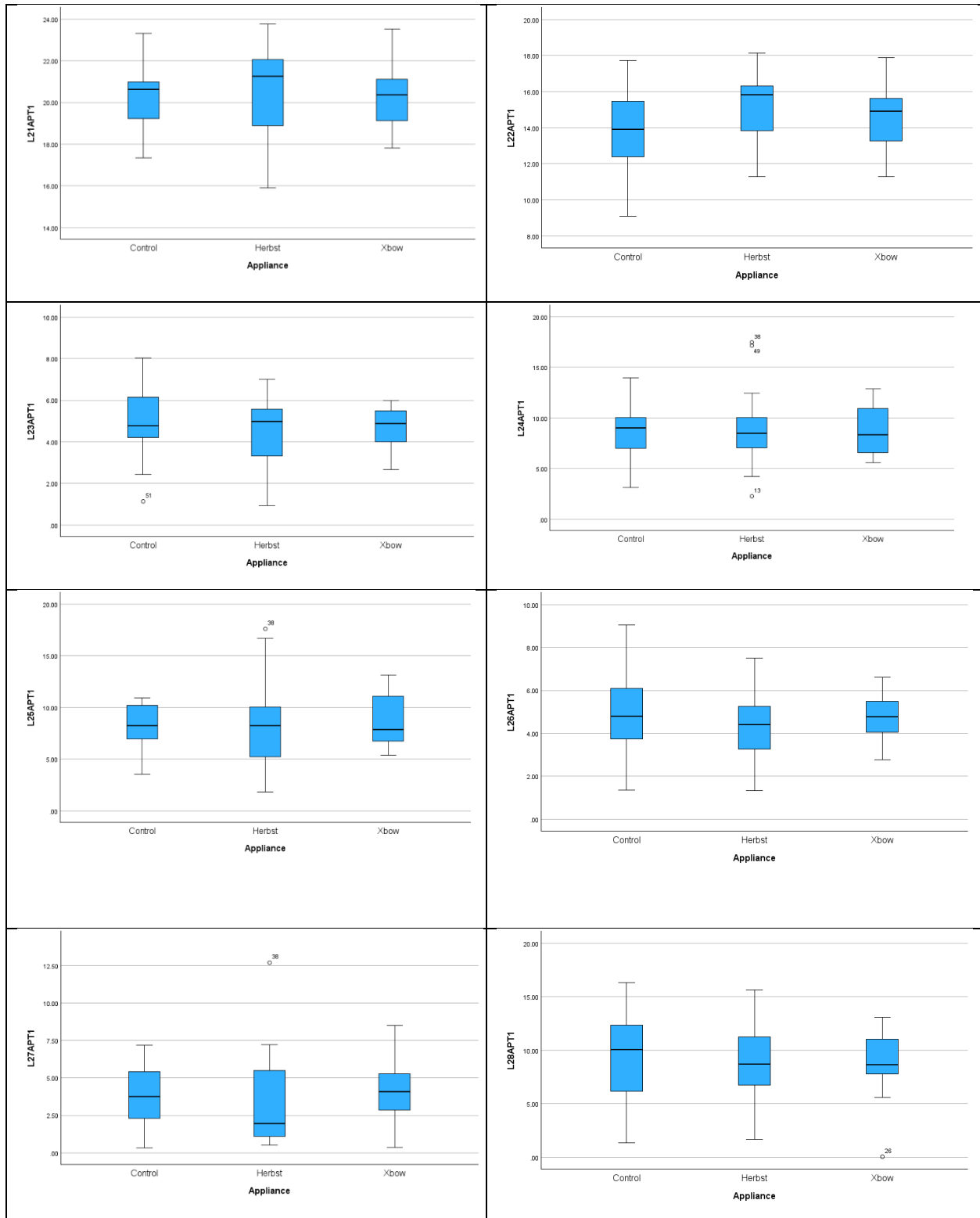


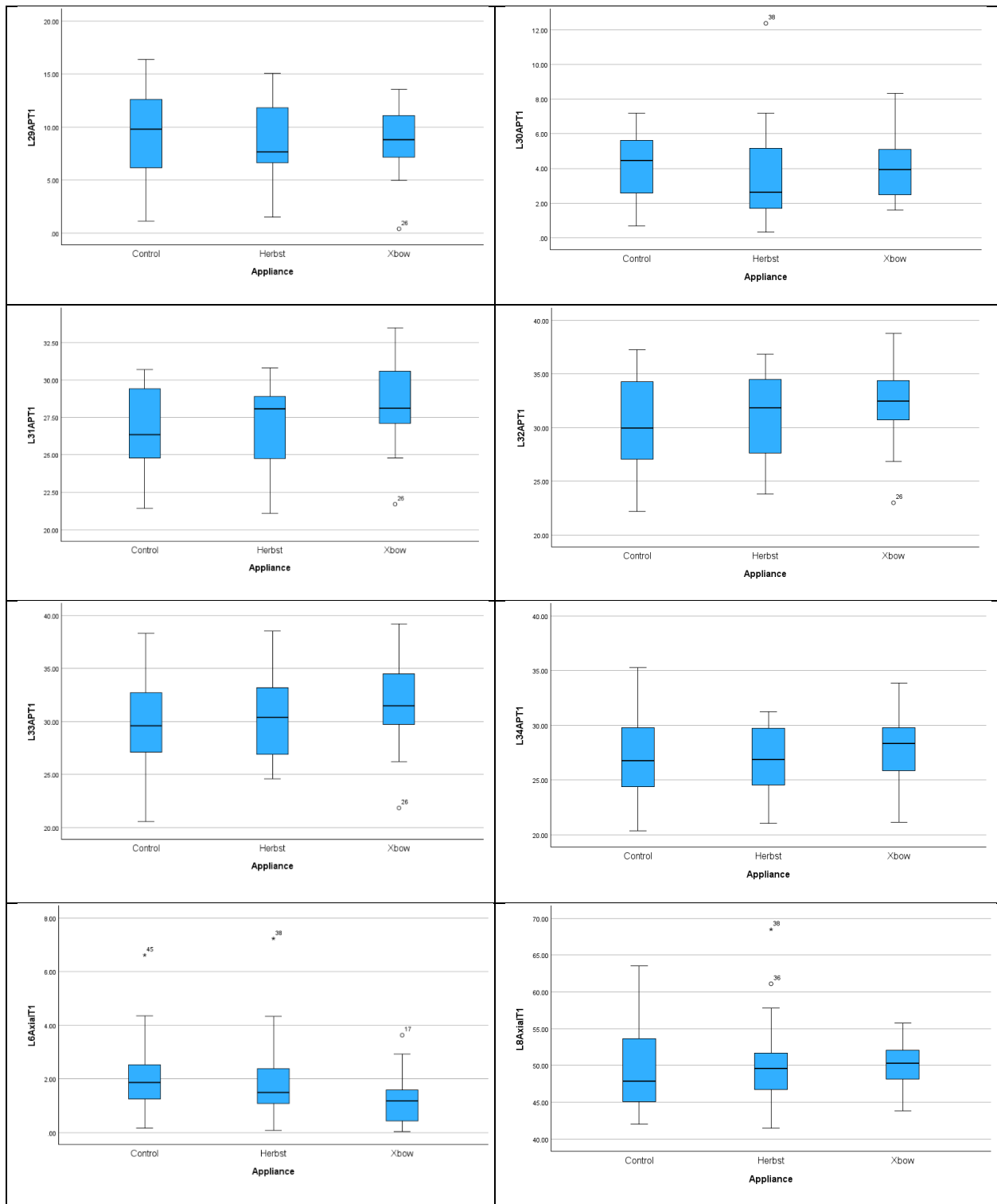


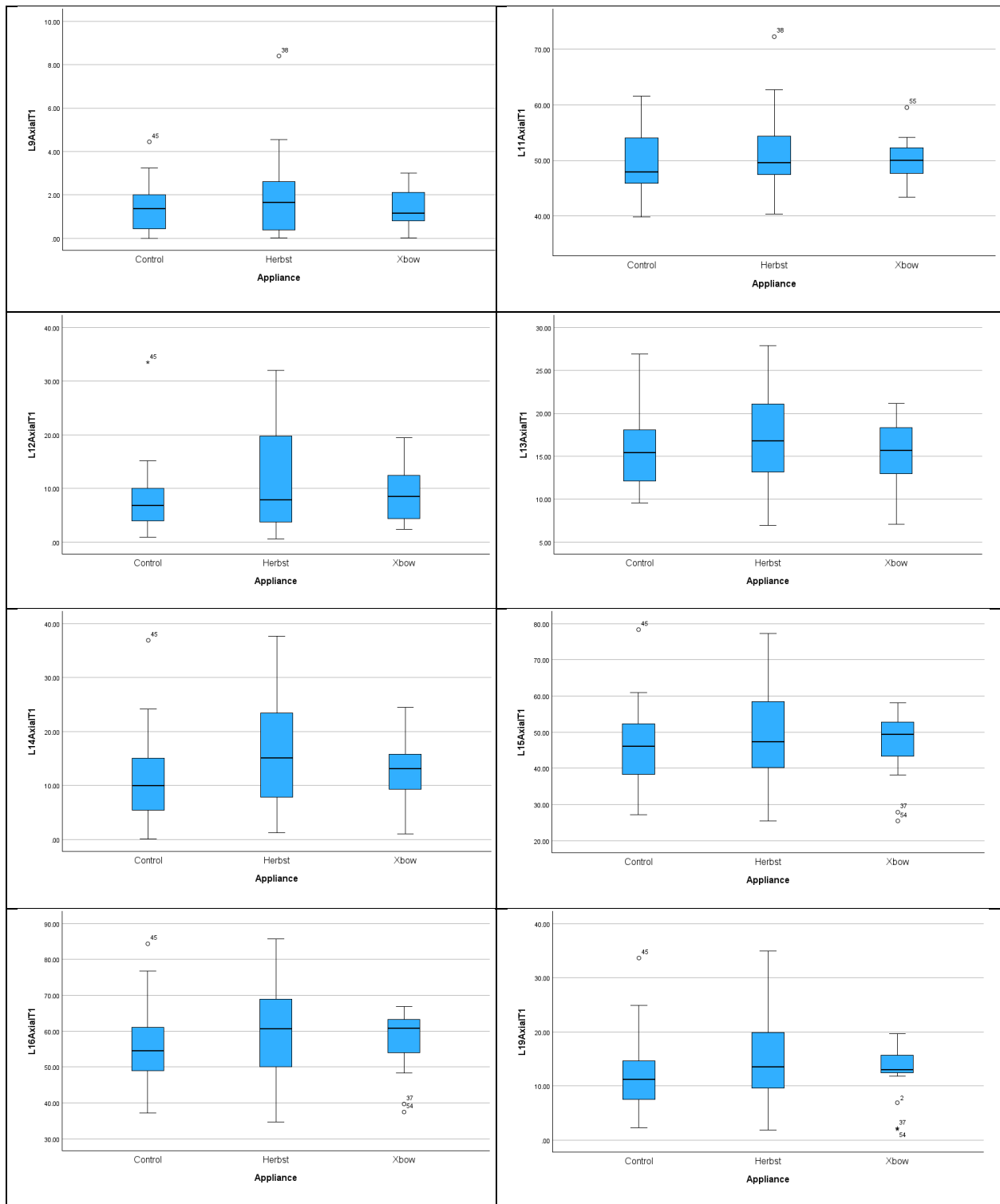


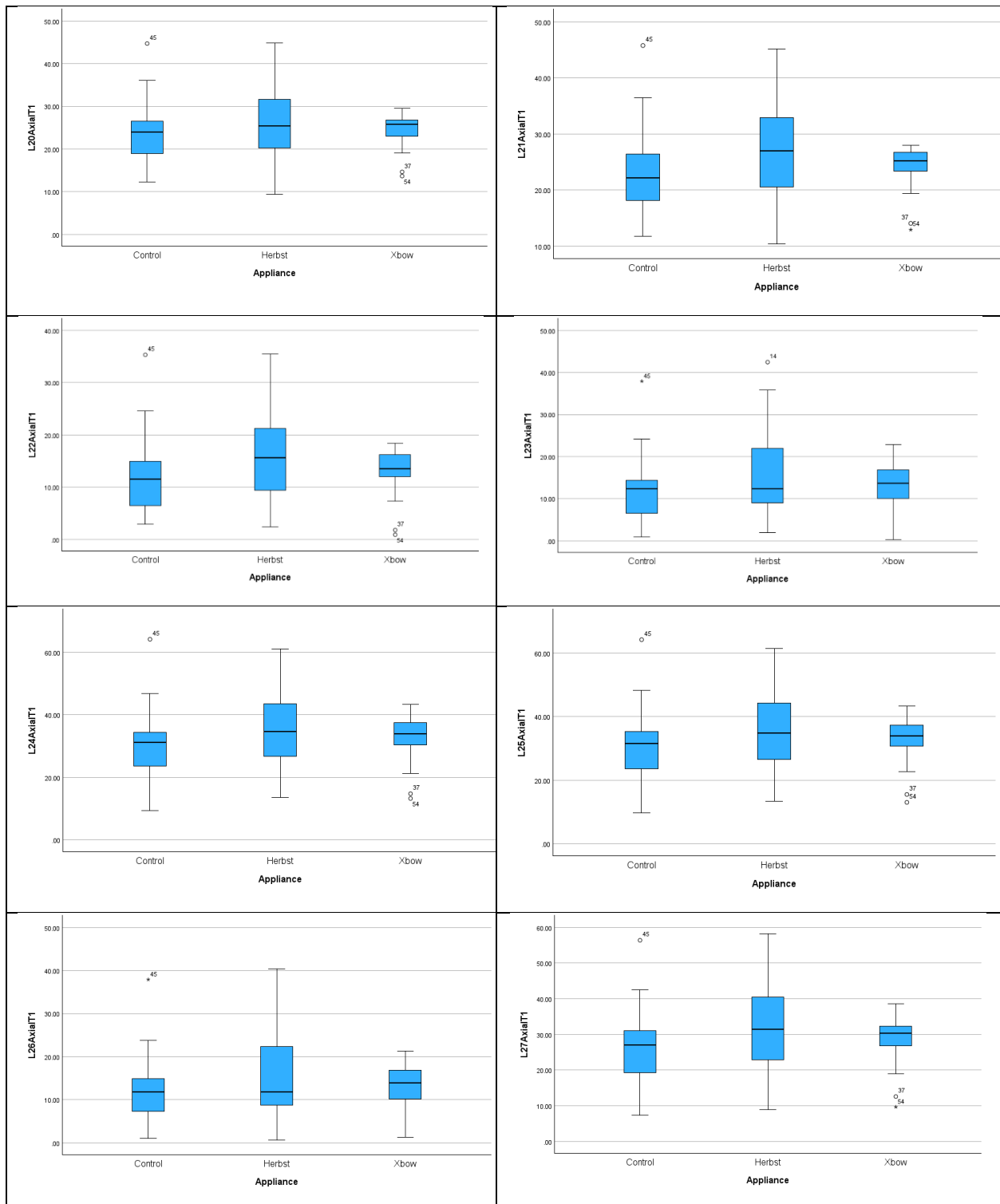


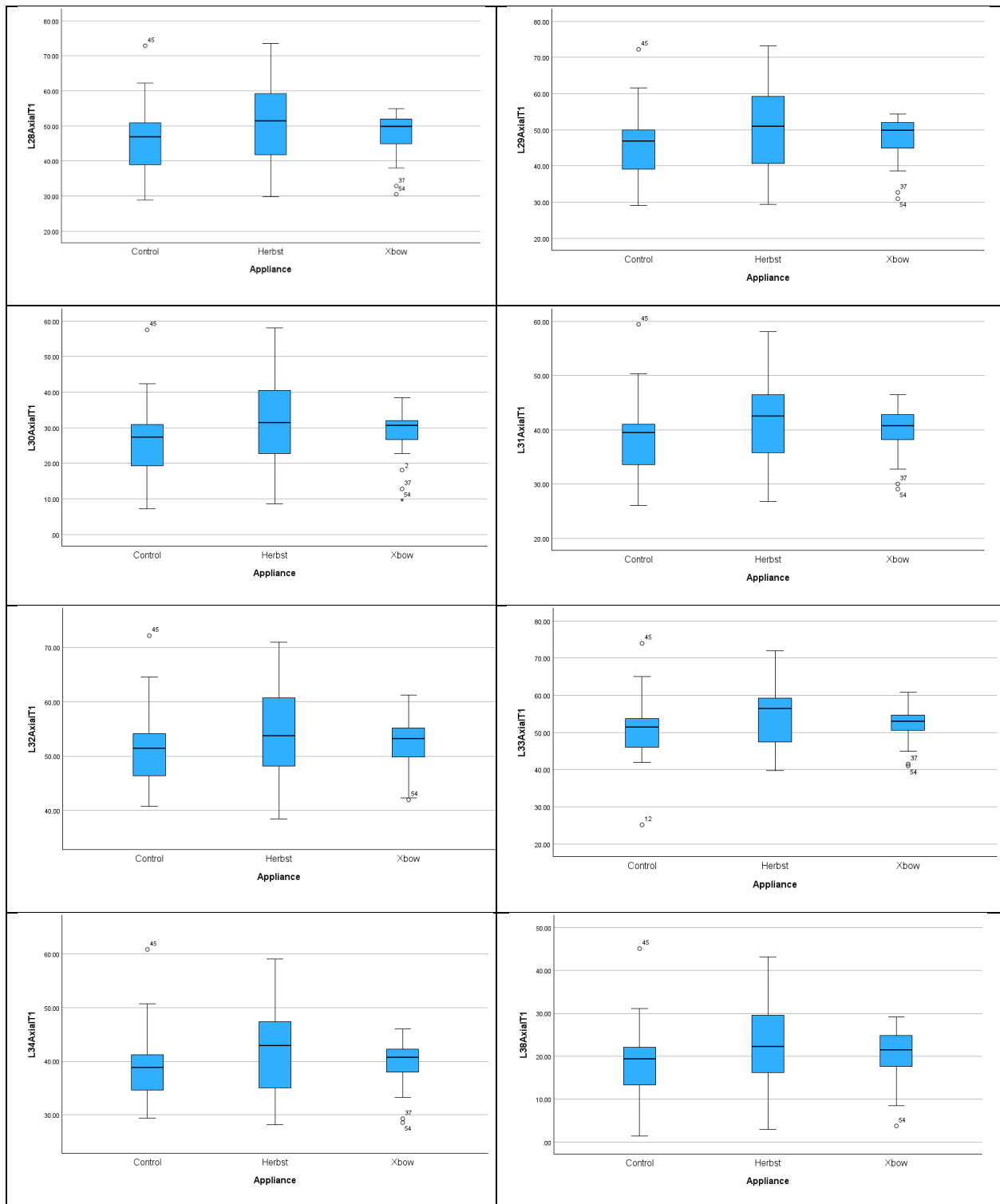












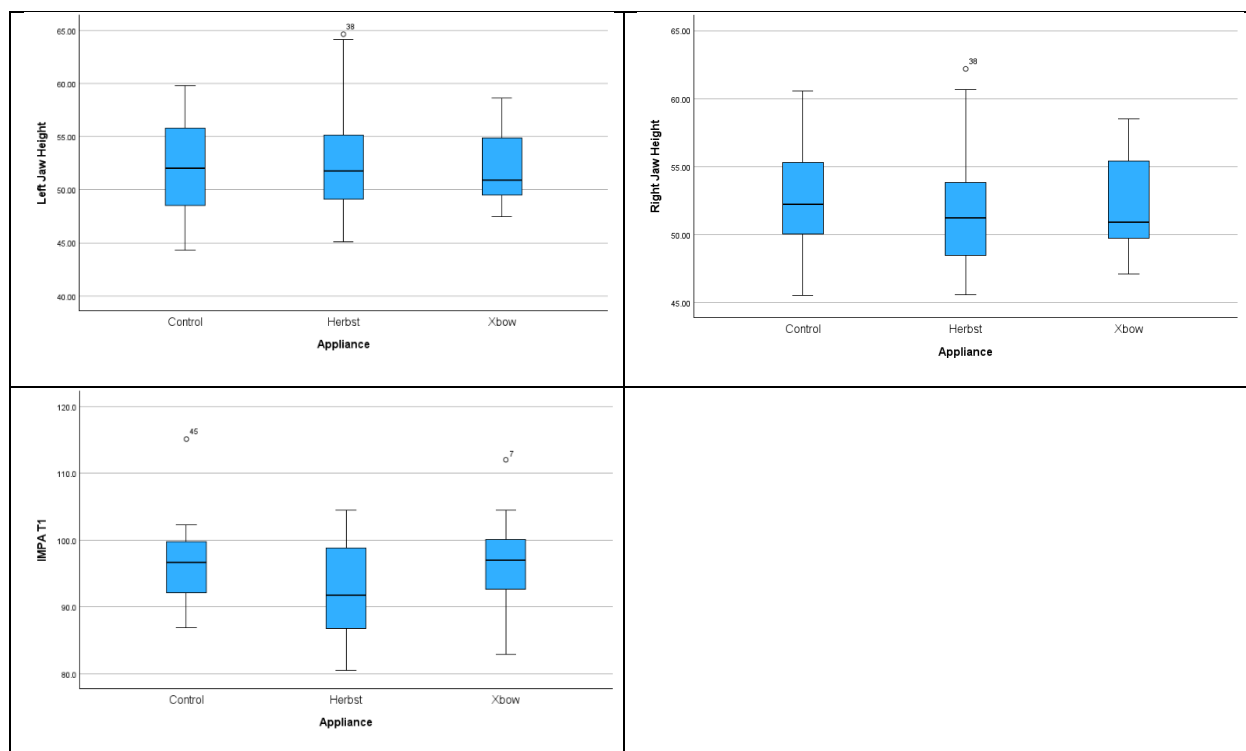


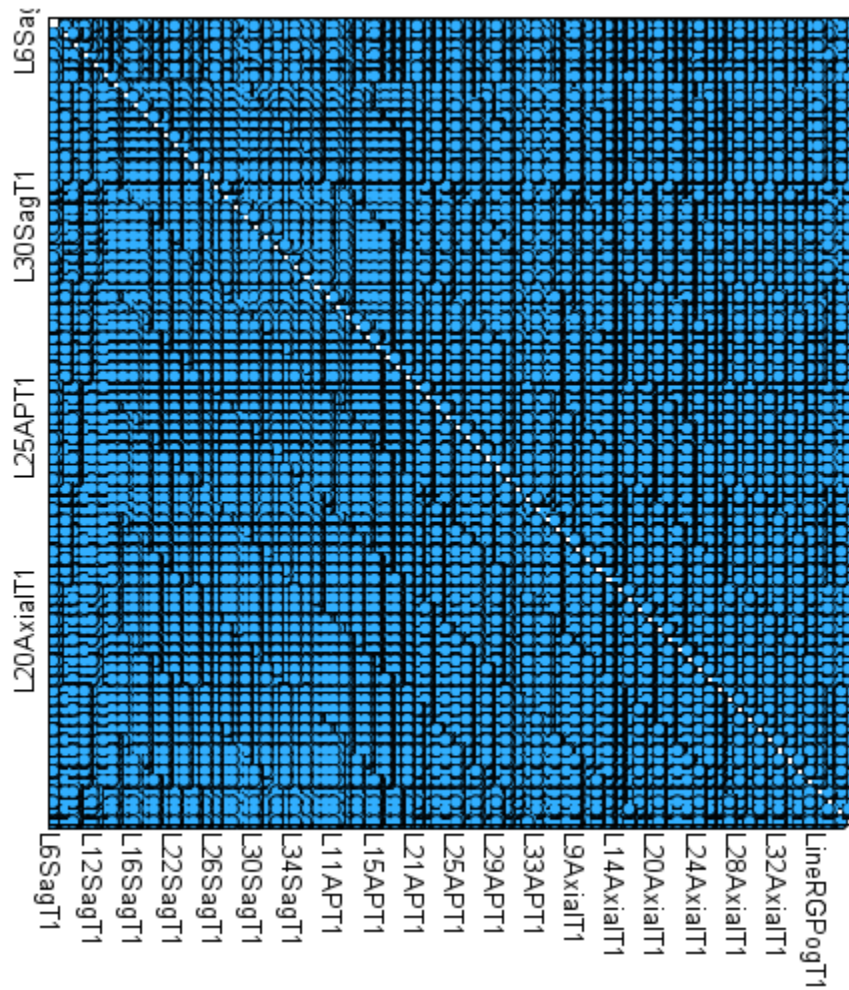
Table 12. MANOVA at T1 Comparing Treatment Groups

Wilks' Lambda	Value	F	Hypothesis df	Error df	p value
Appliance Extreme Outliers Removed	0.001	0.542	94.000	2.000	0.837
Sagittal Direction Isolated	0.300	1.059	50.000	64.000	0.412
AP Direction Isolated	0.294	1.080	50.000	64.000	0.383
AP Direction Multivariate Outlier Removed	0.284	1.088	50.000	62.000	0.374
Axial Direction Isolated	0.287	1.032	52.000	62.000	0.450
Axial Direction Multivariate Outlier Removed	0.295	0.972	52.000	60.000	0.539
Md Body Length, Ramus Height, IMPA Isolated	0.863	0.789	10.000	104.000	0.634

Table 13. Box's Test of Equality of Covariance Matrices T1

Variables Included	Box's M	F	df1	df2	p value
Sagittal Skeletal	118.074	1.004	90	8445.778	0.471
AP Skeletal	136.677	1.162	90	8445.778	0.142
Axial Skeletal	331.805	1.198	182	8172.404	0.037
Sagittal Dental	563.988	1.190	272	8088.947	0.019
AP Dental	569.718	1.202	272	8088.947	0.014
Axial Dental	869.889	1.551	306	8070.557	<0.001

Figure 5. Scatter Matrix for MANOVA at T1 and Selected Examples



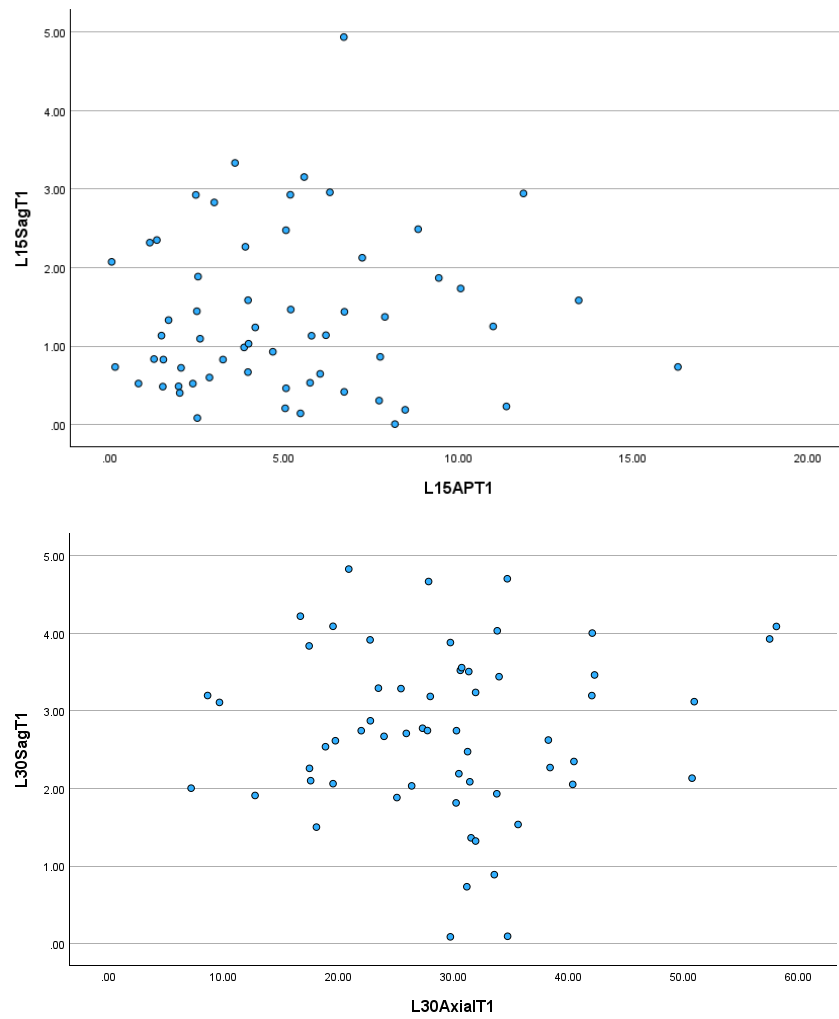
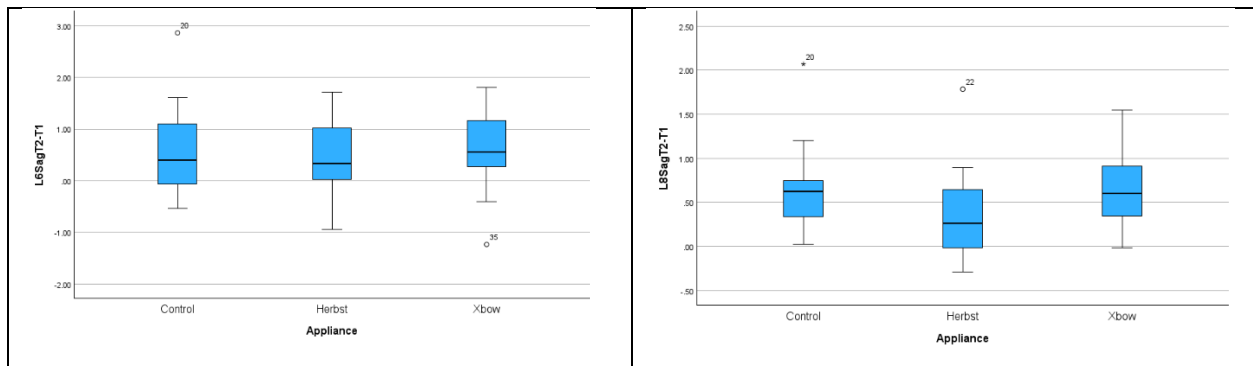
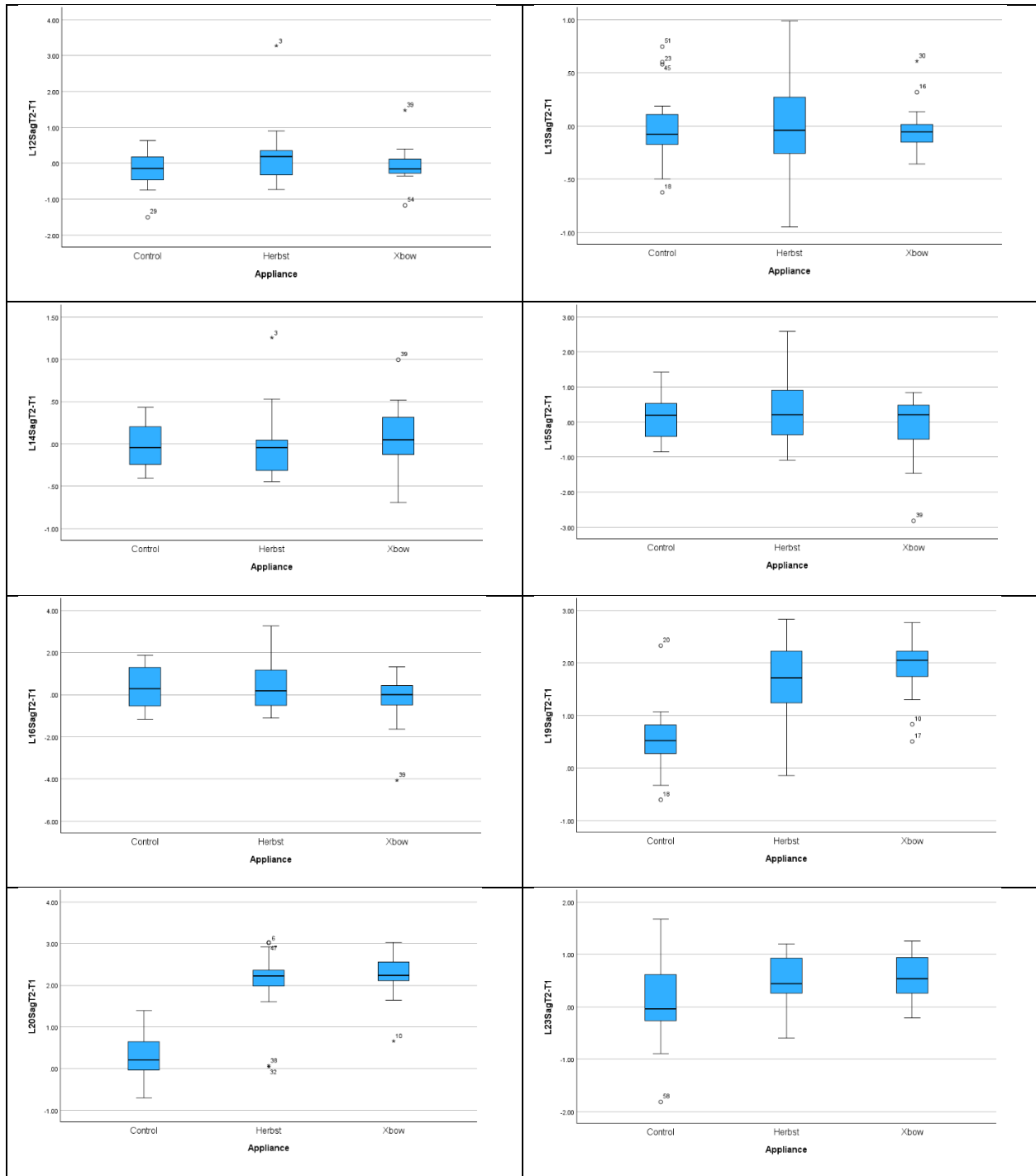
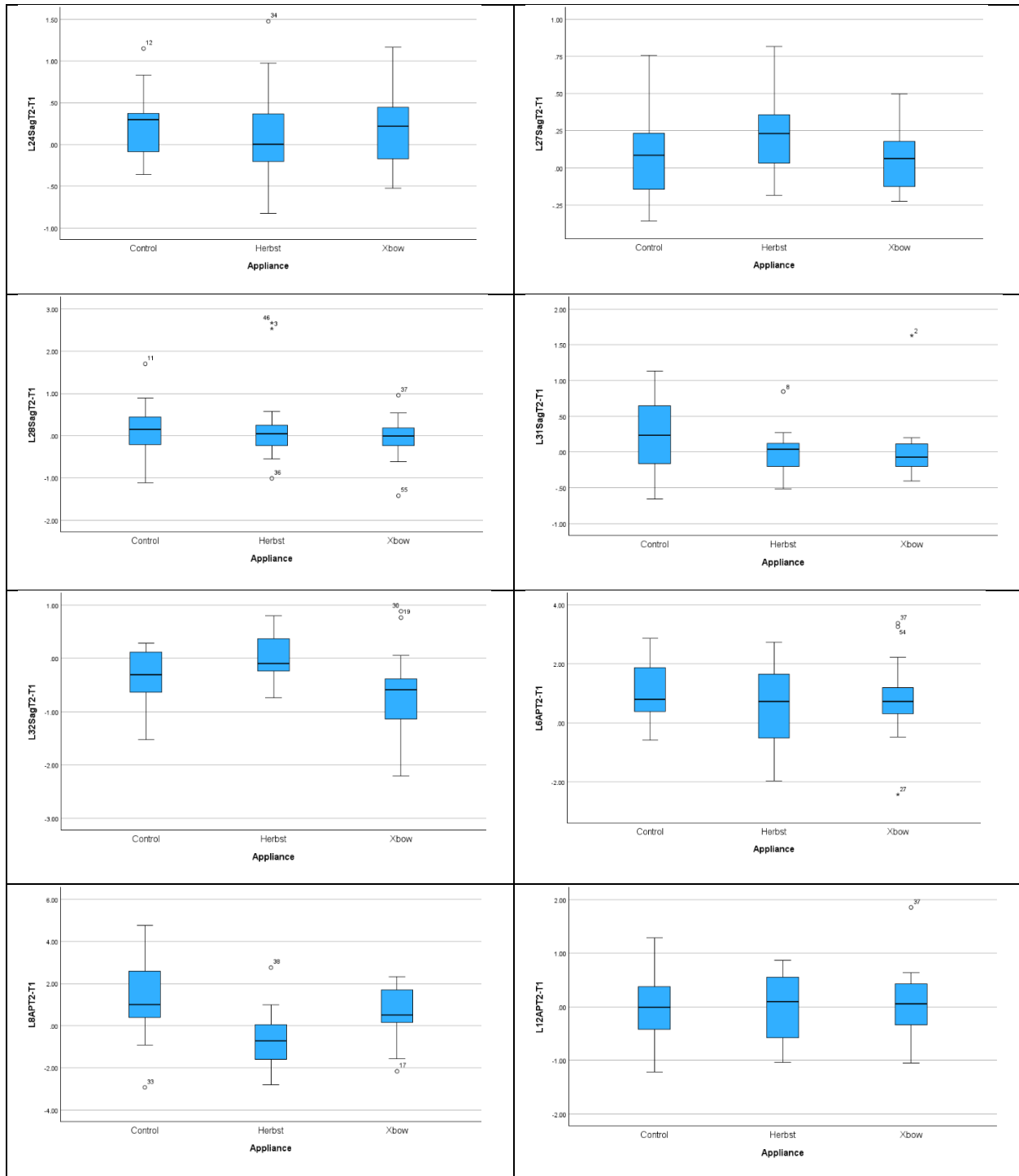
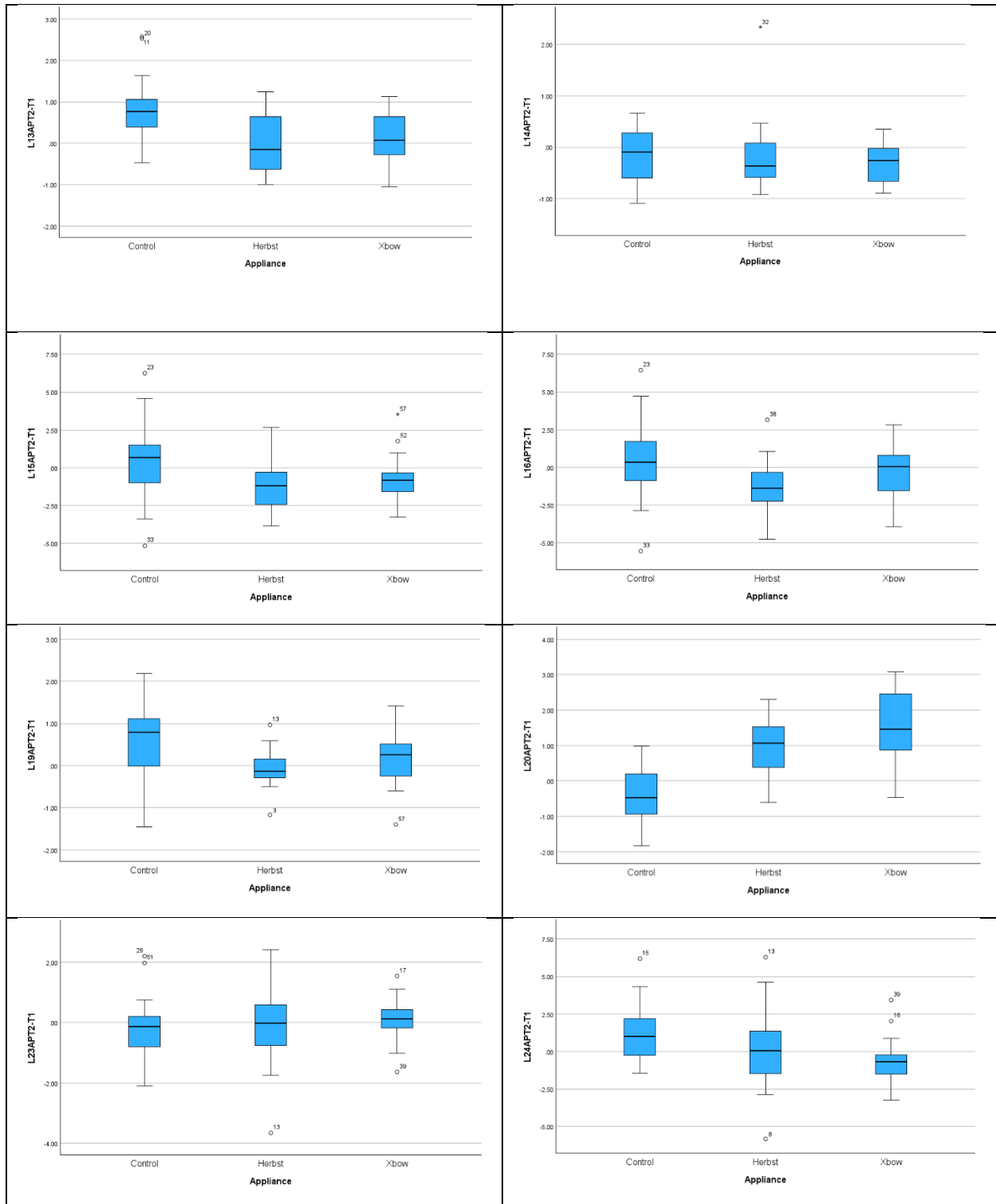


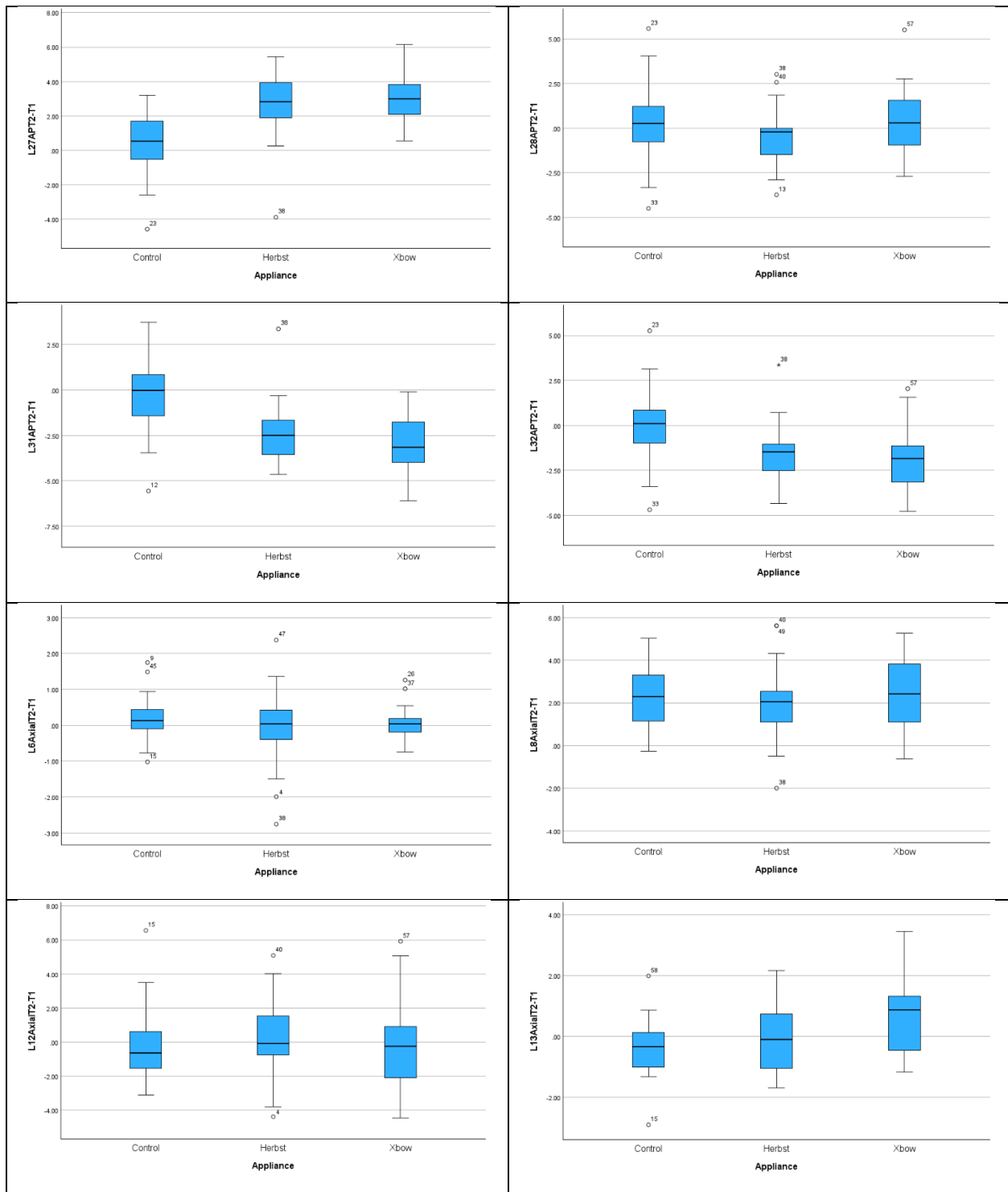
Figure 6. Boxplots for MANOVA T2-T1

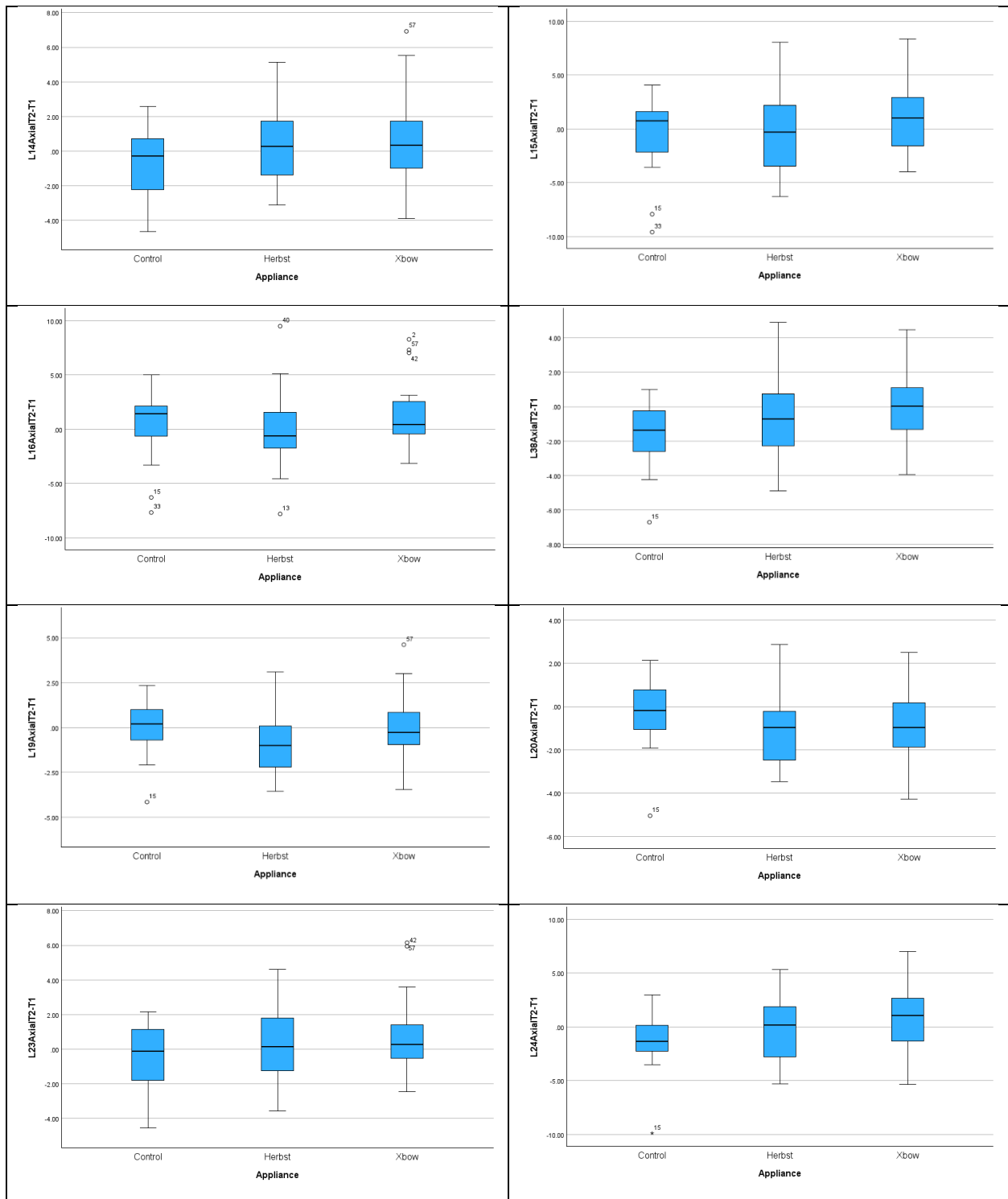












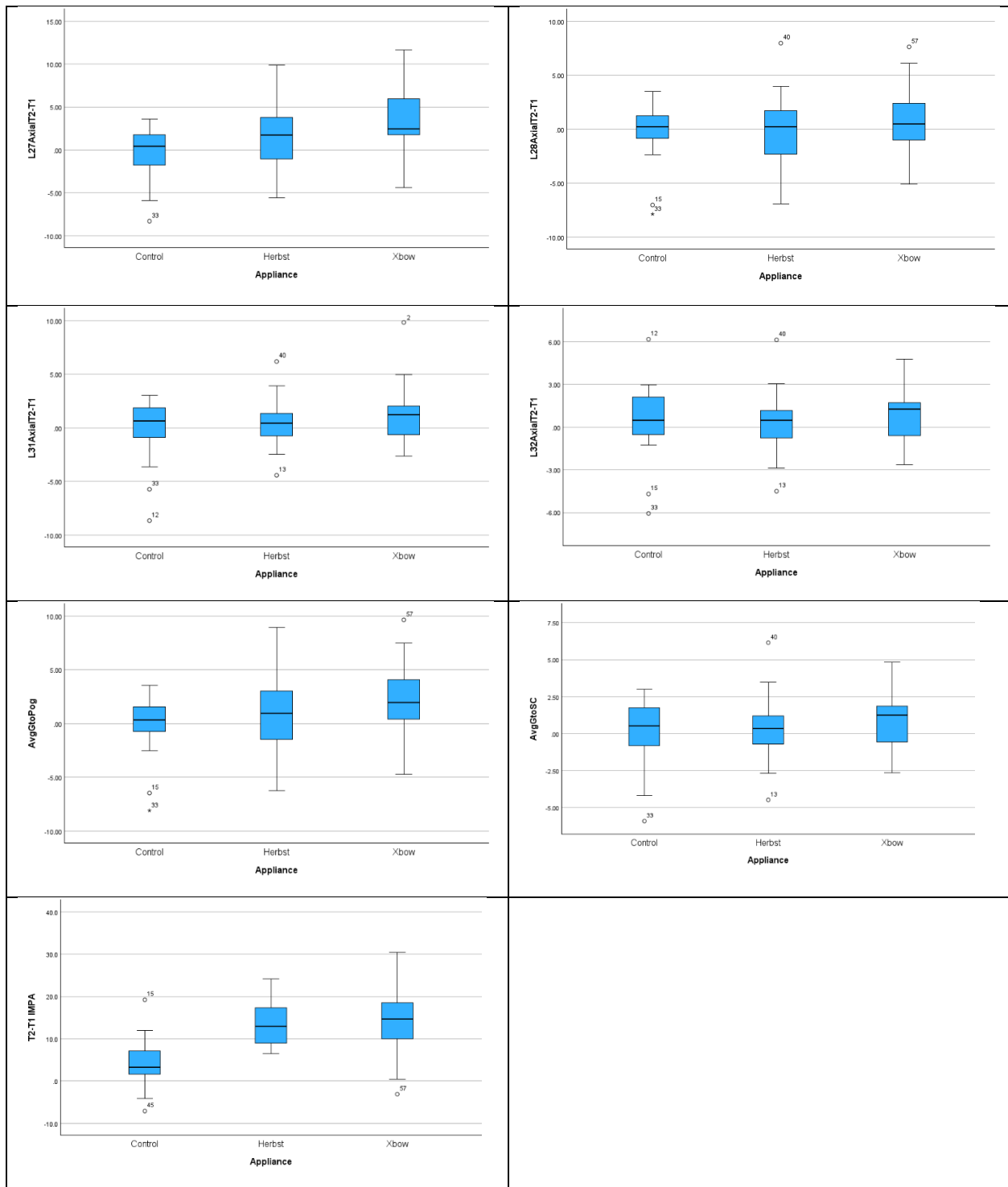


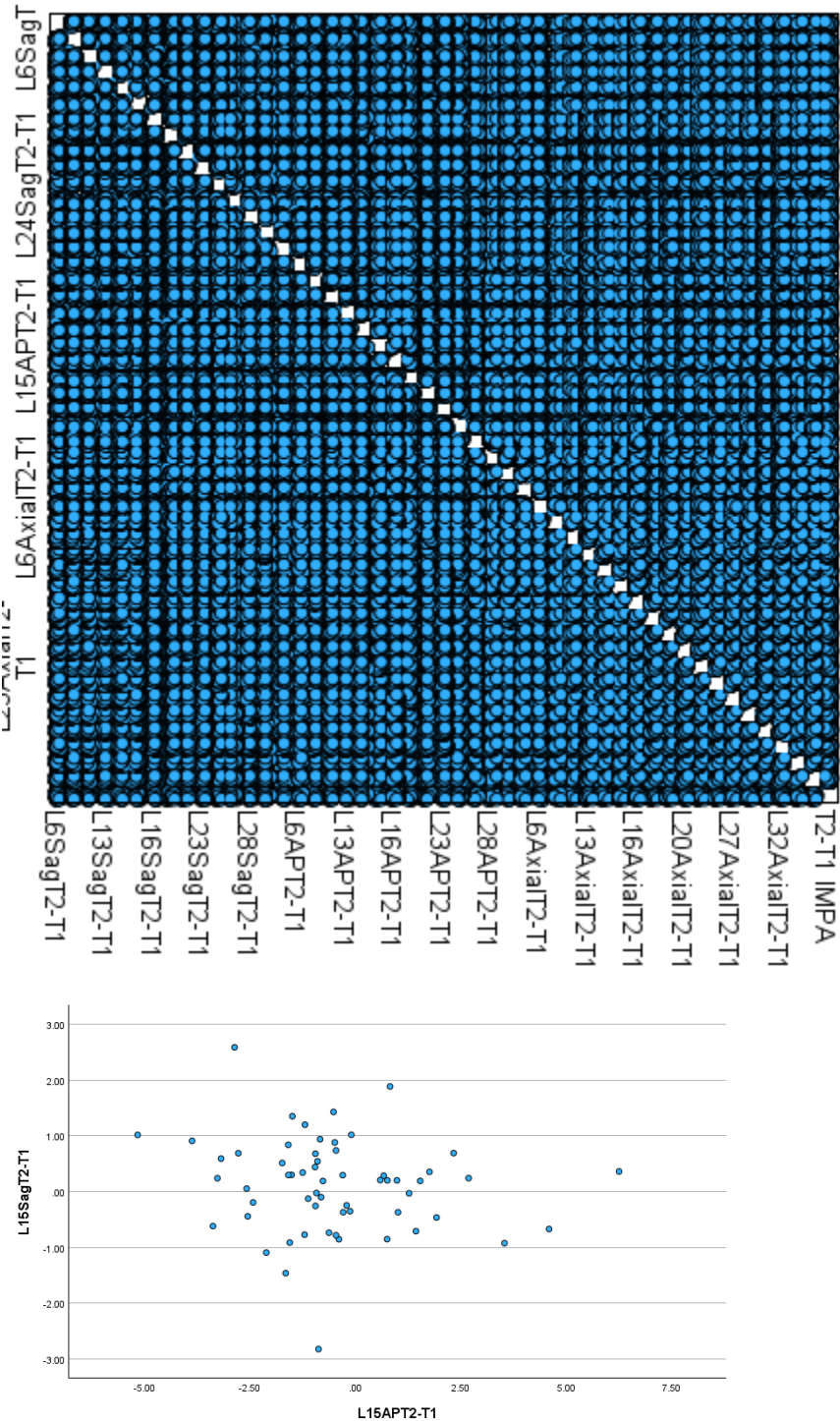
Table 14. MANOVA of T2-T1 Comparing Treatment Groups

Wilks' Lambda	Value	F	Hypothesis df	Error df	p value
Appliance Extreme Outliers Removed	0.001	3.032	88.000	2.000	<0.001
Sagittal Direction Isolated	0.139	4.706	30.000	84.000	<0.001
Sagittal Direct. Multivariate Outlier Removed	0.143	4.501	30.000	82.000	<0.001
AP Direction Isolated	0.152	4.383	30.000	84.000	<0.001
AP Direction Multivariate Outlier Removed	0.157	4.164	30.000	82.000	<0.001
Axial Direction Isolated	0.222	2.880	32.000	82.000	<0.001
Axial Direction Multivariate Outlier Removed	0.225	2.772	32.000	80.000	<0.001
Md Body Length, Ramus Height, IMPA Isolated	0.614	4.981	6.000	108.000	<0.001
Md Body Length, Ramus Height, IMPA Multivariate Outlier Removed	0.586	5.418	6.000	106.000	<0.001

Table 15. Box's Test of Equality of Covariance Matrices T2-T1

Variables Included	Box's M	F	df1	df2	p value
Sagittal Skeletal	107.870	1.575	56	8804.414	0.004
AP Skeletal	105.460	1.540	56	8804.414	0.006
Axial Skeletal	183.555	1.232	110	8344.811	0.051
Sagittal Dental	155.680	1.711	72	8589.418	<0.001
AP Dental	172.080	1.891	72	8589.418	<0.001
Axial Dental	256.280	2.178	90	8445.778	<0.001

Figure 7 Scatter Matrix for MANOVA for T2-T1 and Selected Examples



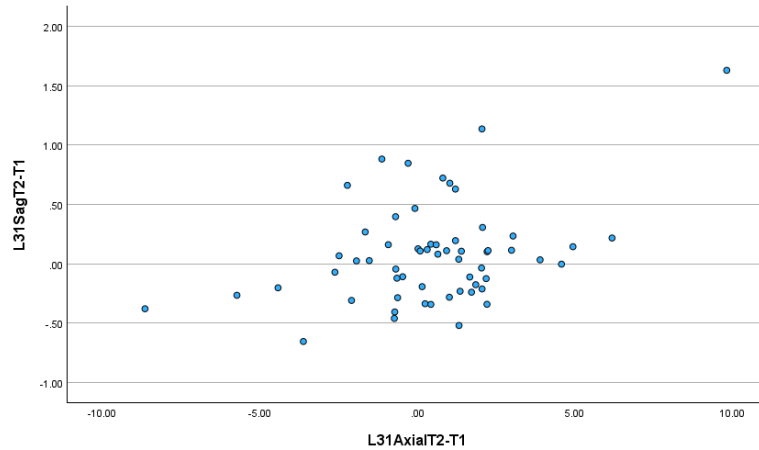


Table 16. Assumption testing for One-way Repeated Measures ANOVA

Assumptions tested for in a One-Way Repeated Measures ANOVA include:

1. Normality
2. Linearity
3. Sphericity
4. Equal variance-covariance matrices (Box's M-test)

For each ANOVA normality and presence of outliers was assessed by inspection of boxplots. If extreme outliers were present, they were removed and the ANOVA was run again to determine if the removal changed the ANOVA result. Linearity was assessed by inspection of scatterplot. Assumption of sphericity tested with Mauchly's test of sphericity and if sphericity violated then a Greenhouse-Geisser correction performed. A repeated measures test is sensitive to variance differences which biases the test towards a Type I error and a false positive result (45). To account for this since we are investigating skeletal and dental landmarks separately it was decided to divide the typical α or 0.05 by 2, in essence using an α of 0.025 for Greenhouse-Geisser correction. Homogeneity of variance-covariance matrices were assessed by Box's M-test.

Skeletal Sagittal

Outliers noted in boxplots in Figure 8 in appendix. When extreme outliers removed, sphericity was violated with a p value of <0.001 (Table 16 in appendix) and Greenhouse-

Geisser p value >0.025 being 0.321 (Table 17 in appendix). Since these results were consistent, compared to when outliers included, extreme outliers were included in the ANOVA. There was homogeneity of variance-covariance matrices, as assessed by Box's test of equality of covariance matrices with p value greater than 0.001 being 0.004 (Table 18 in appendix). There were linear relationships between sagittal variables as assessed by scatterplot (Figure 9 in appendix).

Skeletal Anteroposterior

Outliers noted in boxplots in Figure 10 in appendix. When extreme outliers removed, sphericity was violated with a p value of <0.001 (Table 16 in appendix) and Greenhouse-Geisser p value >0.025 being 0.058 (Table 17 in appendix). Since these results were consistent, compared to when outliers included, extreme outliers were included in the ANOVA. There was homogeneity of variance-covariance matrices, as assessed by Box's test of equality of covariance matrices with p value greater than 0.001 being 0.006 (Table 18 in appendix). There were linear relationships between sagittal variables as assessed by scatterplot (Figure 11 in appendix).

Skeletal Axial

Outliers noted in boxplots in Figure 12 in appendix. When extreme outliers removed, sphericity was violated with a p value of <0.001 (Table 16 in appendix) and Greenhouse-Geisser p value >0.025 being 0.432 (Table 17 in appendix). Since these results were consistent, compared to when outliers included, extreme outliers were included in the ANOVA. There was homogeneity of variance-covariance matrices, as assessed by Box's test of equality of covariance matrices with p value greater than 0.001 being 0.048 (Table 18 in appendix). There were linear relationships between sagittal variables as assessed by scatterplot (Figure 13 in appendix).

Dental Sagittal

Outliers noted in boxplots in Figure 14 in appendix. When extreme outliers removed, sphericity was violated with a p value of <0.001 (Table 16 in appendix) and Greenhouse-Geisser p value <0.025 being <0.001 (Table 17 in appendix). Since these results were

consistent, compared to when outliers included, extreme outliers were included in the ANOVA. There was not homogeneity of variance-covariance matrices, as assessed by Box's test of equality of covariance matrices with p value <0.001 (Table 18 in appendix). With similar sample sizes (Table 19 in appendix) between groups the violation of the homogeneity of variances-covariance matrices should not effect the results significantly so the decision was made to continue with the one-way repeated measures ANOVA. There were linear relationships between sagittal variables as assessed by scatterplot (Figure 15 in appendix).

Dental Anteroposterior

Outliers noted in boxplots in Figure 16 in appendix. When extreme outliers removed, sphericity was violated with a p value of <0.001 (Table 16 in appendix) and Greenhouse-Geisser p value <0.025 being <0.001 (Table 17 in appendix). Since these results were consistent, compared to when outliers included, extreme outliers were included in the ANOVA. There was not homogeneity of variance-covariance matrices, as assessed by Box's test of equality of covariance matrices with p value <0.001 (Table 18 in appendix). With similar sample sizes (Table 19) between groups the violation of the homogeneity of variances-covariance matrices should not effect the results significantly so the decision was made to continue with the one-way repeated measures ANOVA. There were linear relationships between sagittal variables as assessed by scatterplot (Figure 17 in appendix).

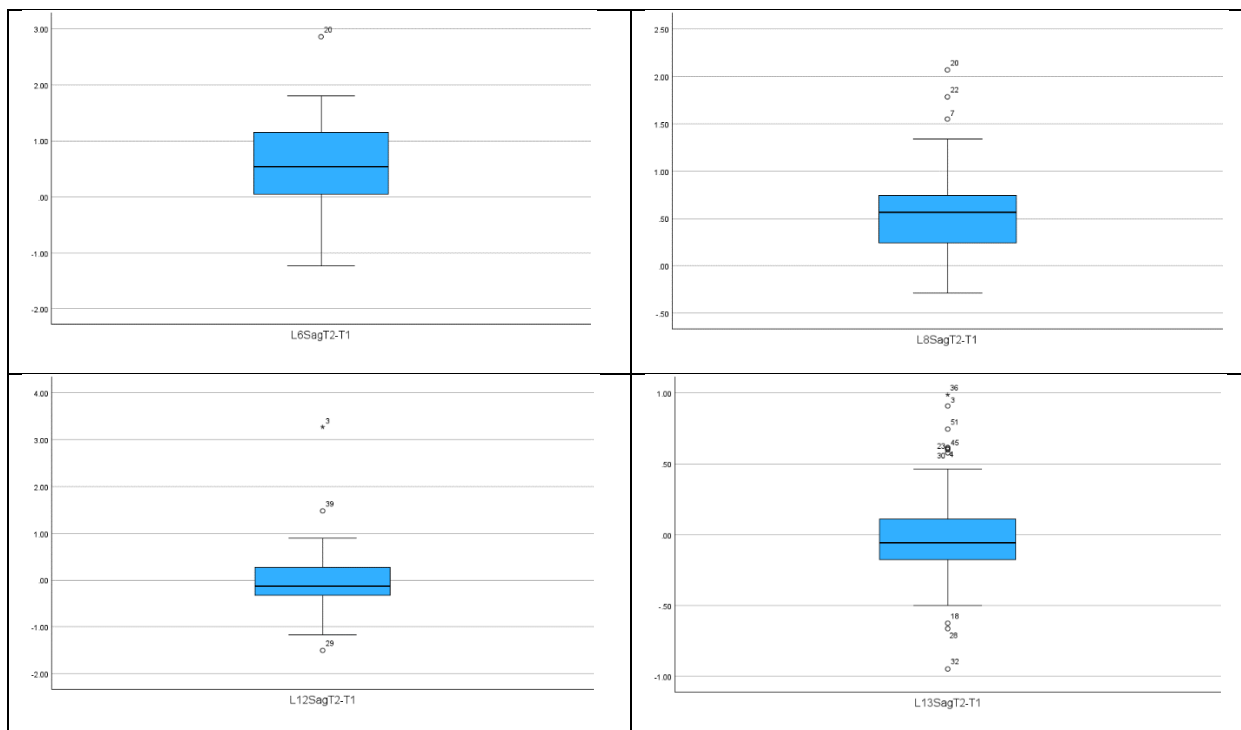
Dental Axial

Outliers noted in boxplots in Figure 18 in appendix. There were no extreme outliers to remove. There was not homogeneity of variance-covariance matrices, as assessed by Box's test of equality of covariance matrices with p value <0.001 (Table 18 in appendix). With similar sample sizes (Table 19) between groups the violation of the homogeneity of variances-covariance matrices should not effect the results significantly so the decision was made to continue with the one-way repeated measures ANOVA. There were linear relationships between sagittal variables as assessed by scatterplot (Figure 19 in appendix).

Mandibular Body Length, Ramus Height, IMPA

Outliers noted in boxplots in Figure 20 in appendix. When extreme outliers removed, sphericity was violated with a p value of <0.001 (Table 16 in appendix) and Greenhouse-Geisser p value <0.025 being <0.001 (Table 17 in appendix). Since these results were consistent, compared to when outliers included, extreme outliers were included in the ANOVA. There was homogeneity of variance-covariance matrices, as assessed by Box's test of equality of covariance matrices with p value greater than 0.001 being 0.102 (Table 18 in appendix). There were linear relationships between sagittal variables as assessed by scatterplot (Figure 21 in appendix).

Figure 8. Boxplots for One-Way Repeated Measures ANOVA Skeletal Sagittal



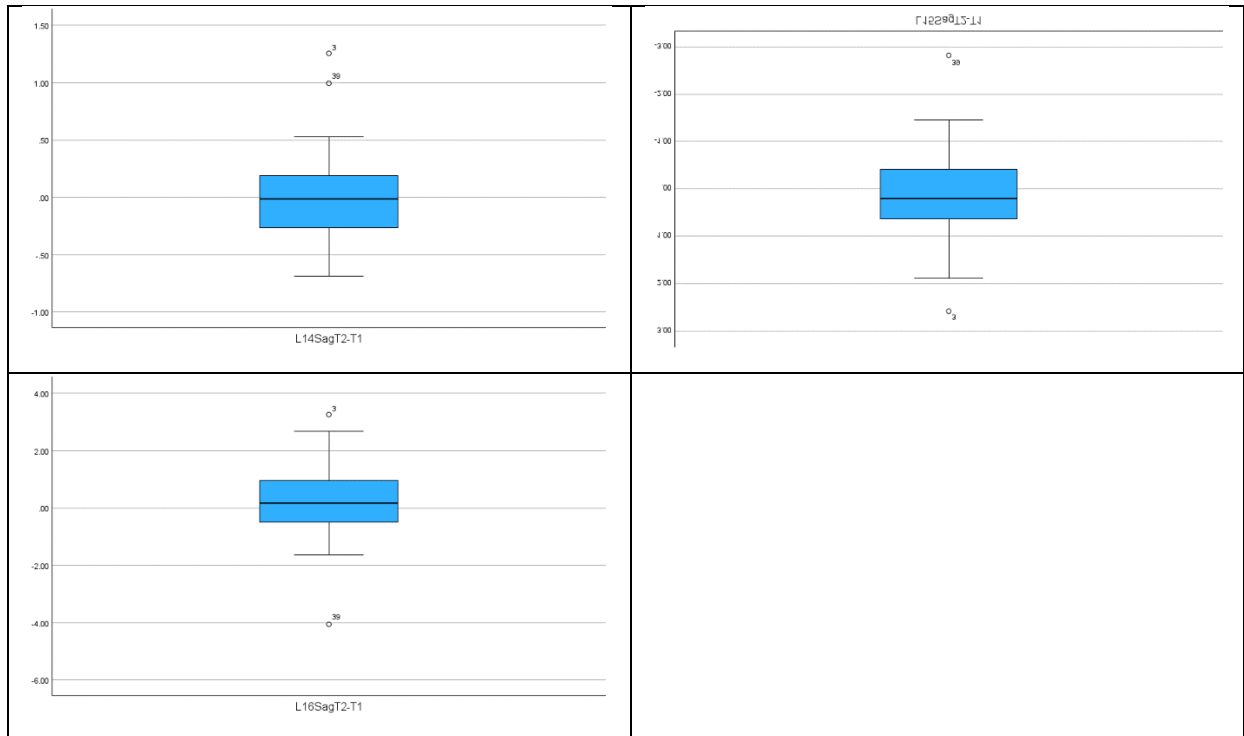


Table 17. Mauchly's Test of Sphericity One-Way Repeated Measures ANOVA

Variable	Chi Square	df	p value
Skeletal Sagittal	172.758	20	<0.001
Skeletal Sagittal No Extreme Outliers	172.874	20	<0.001
Skeletal AP	245.811	20	<0.001
Skeletal AP No Extreme Outliers	251.003	20	<0.001
Skeletal Axial	213.206	27	<0.001
Skeletal Axial No Extreme Outliers	213.118	27	<0.001
Dental Sagittal	88.080	27	<0.001
Dental Sagittal No Extreme Outliers	98.799	27	<0.001
Dental AP	326.618	27	<0.001
Dental AP No Extreme Outliers	309.073	27	<0.001
Dental Axial	217.656	27	<0.001
Jaw Length, Jaw Height, IMPA	72.790	2	<0.001

Jaw Length, Jaw Height, IMPA No Extreme Outliers	72.376	2	<0.001
--	--------	---	--------

Table 18. p-Values of Interaction Term from One-Way Repeated Measures ANOVA

Variable	Epsilon	df	df Error	F	p value
Skeletal Sagittal	0.441	5.295	148.259	1.473	0.199
Skeletal Sagittal No Extreme Outliers	0.406	4.872	131.532	1.184	0.321
Skeletal AP	0.340	4.086	114.400	2.631	0.037
Skeletal AP No Extreme Outliers	0.340	4.084	112.302	2.345	0.058
Skeletal Axial	0.434	6.072	170.019	1.106	0.361
Skeletal Axial No Extreme Outliers	0.432	6.047	166.286	0.994	0.432
Dental Sagittal	0.718	10.054	281.517	13.897	<0.001
Dental Sagittal No Extreme Outliers	0.668	9.351	247.793	16.027	<0.001
Dental AP	0.341	4.775	133.687	6.613	<0.001
Dental AP No Extreme Outliers	0.343	4.809	132.245	6.815	<0.001
Dental Axial	0.516	7.230	202.435	4.970	<0.001
Jaw Length, Jaw Height, IMPA	0.577	2.307	64.598	13.777	<0.001
Jaw Length, Jaw Height, IMPA No Extreme Outliers	0.575	2.301	63.283	12.949	<0.001

Table 19. p-Values of Appliance Term from One-Way Repeated Measures ANOVA

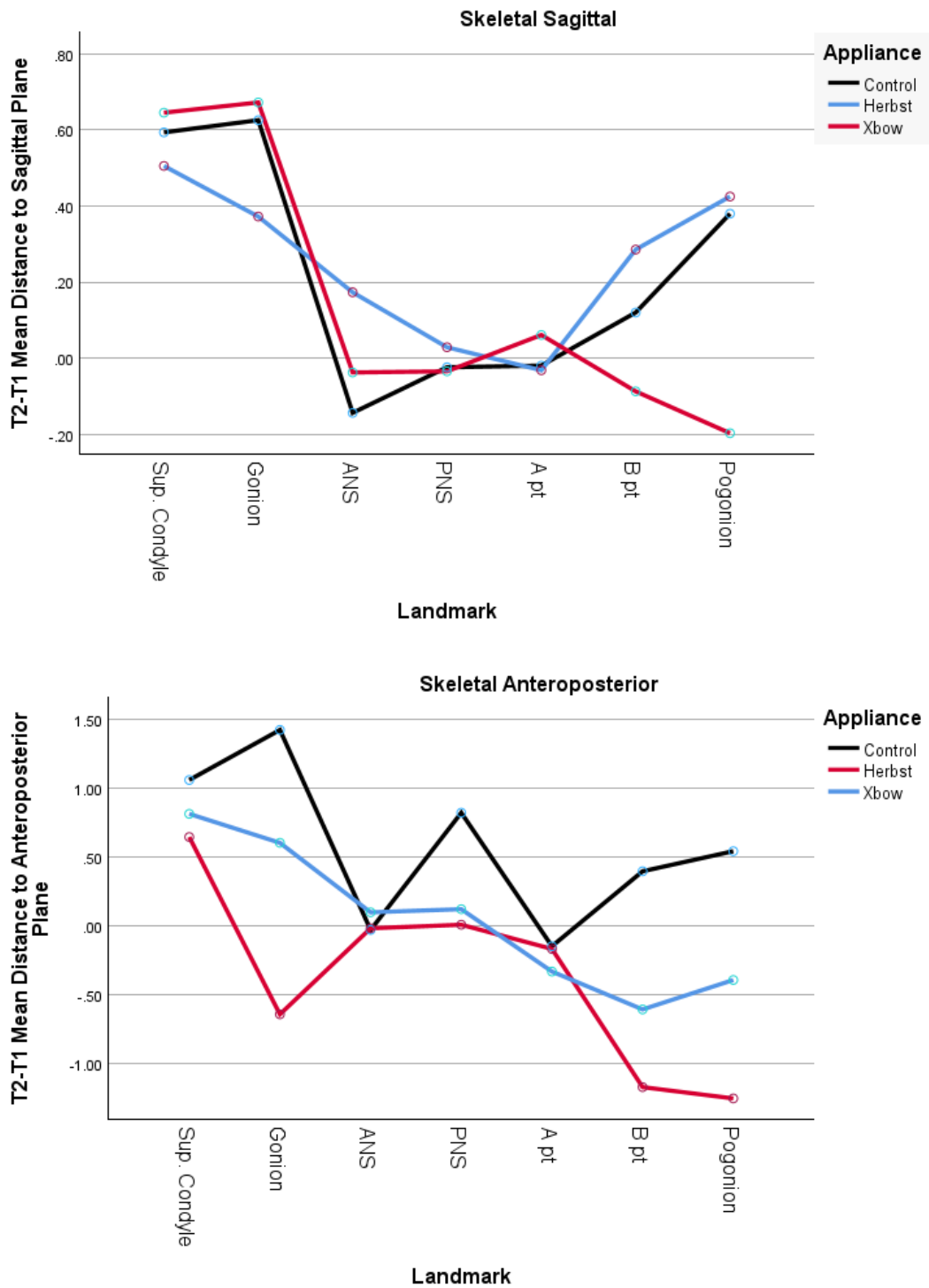
Variable	df	df Error	F	p value
Skeletal Sagittal	2	56	0.466	0.630
Skeletal Sagittal No Extreme Outliers	2	56	0.757	0.474
Skeletal AP	2	56	7.010	0.002
Skeletal AP No Extreme Outliers	2	55	7.055	0.002
Skeletal Axial	2	56	1.250	0.294
Skeletal Axial No Extreme Outliers	2	55	1.175	0.317

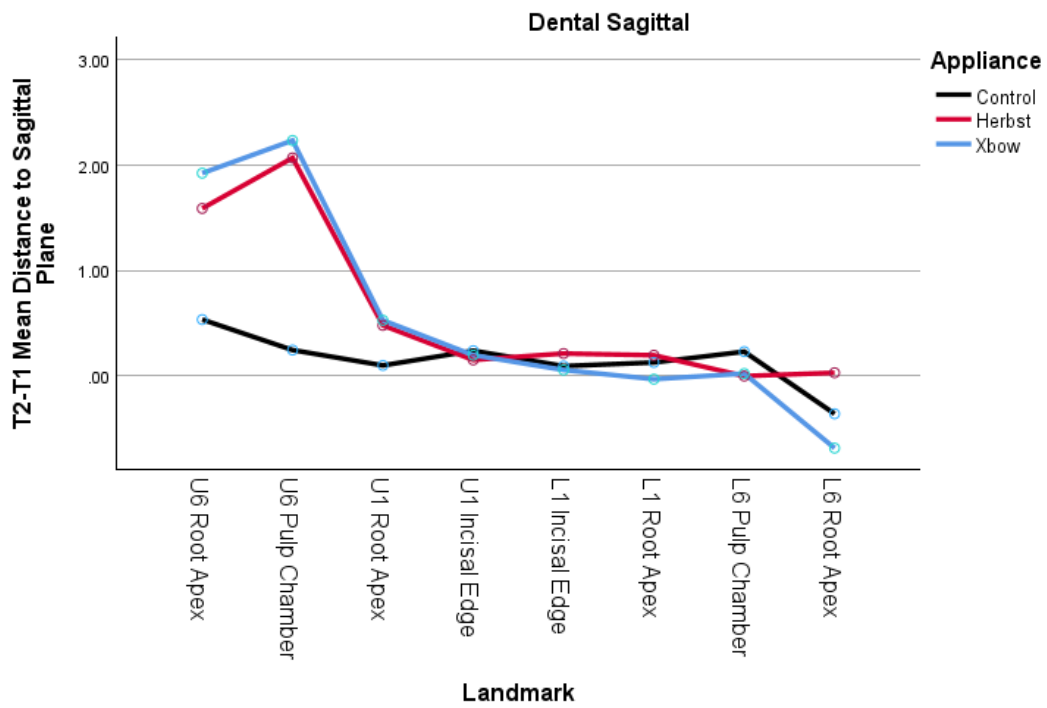
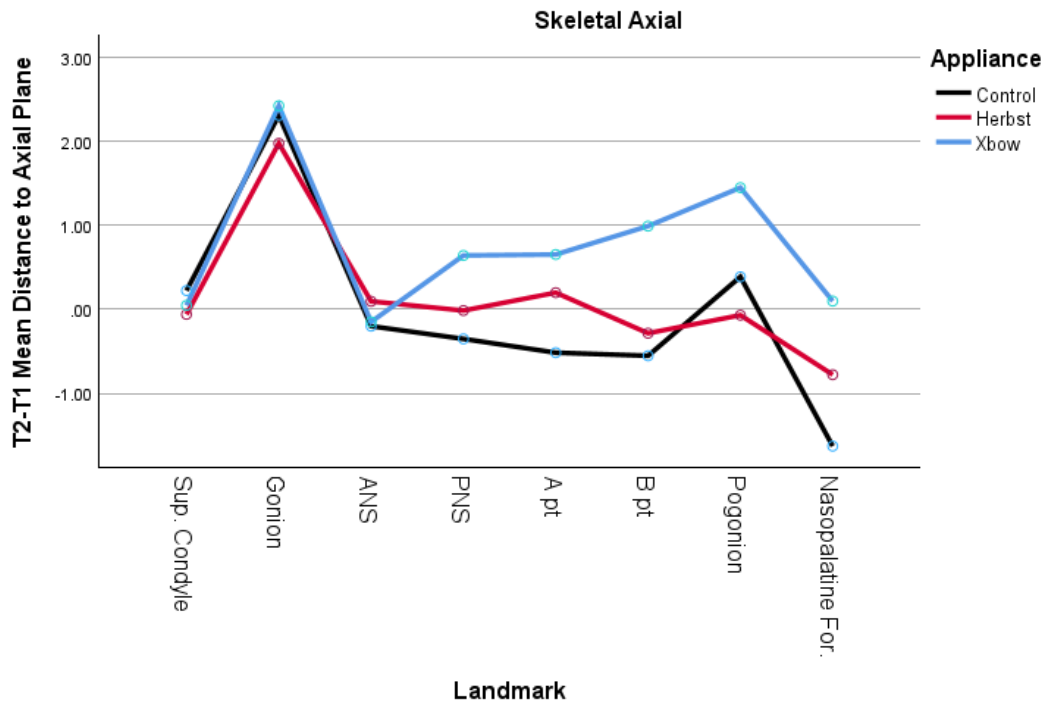
Dental Sagittal	2	56	20.717	<0.001
Dental Sagittal No Extreme Outliers	2	53	18.610	<0.001
Dental AP	2	56	1.404	0.254
Dental AP No Extreme Outliers	2	55	1.311	0.278
Dental Axial	2	56	1.666	0.198
Jaw Length, Jaw Height, IMPA	2	56	13.174	<0.001
Jaw Length, Jaw Height, IMPA No Extreme Outliers	2	55	14.058	<0.001

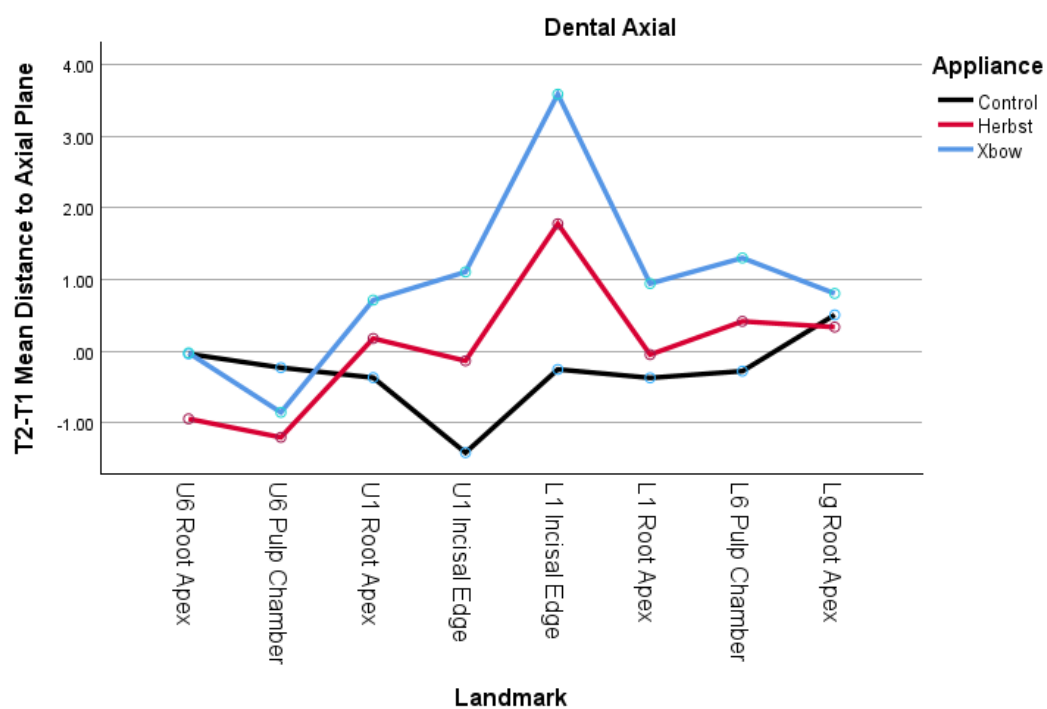
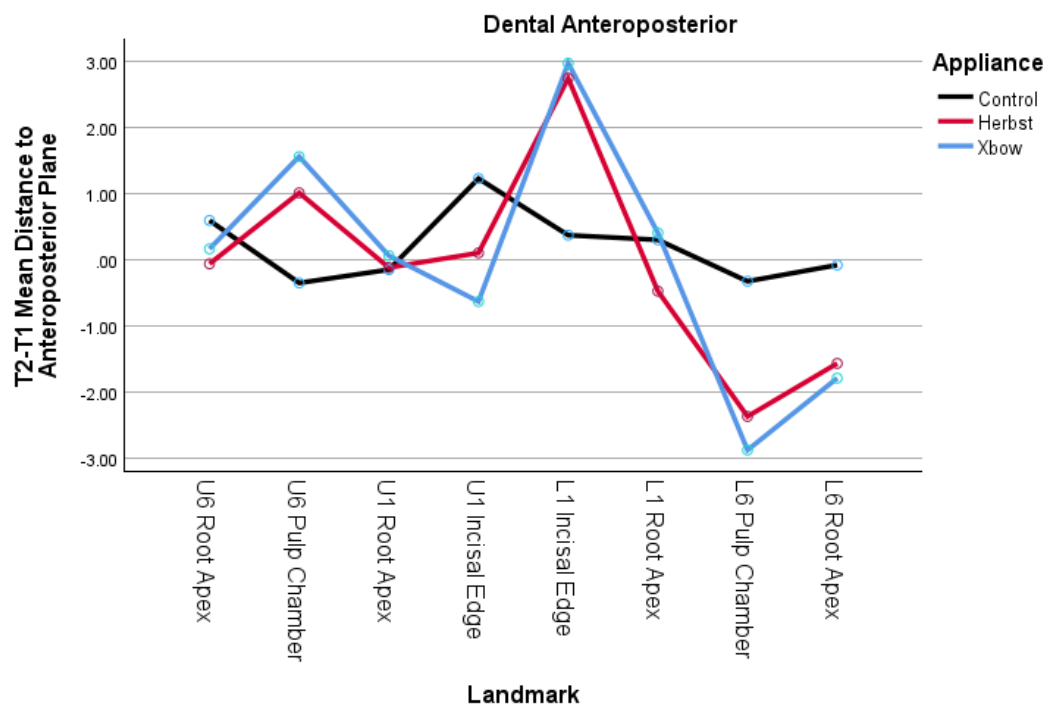
Table 20. p-Values of Landmark Term from One-Way Repeated Measures ANOVA

Variable	df	df Error	F	p value
Skeletal Sagittal	2.647	148.259	9.117	<0.001
Skeletal Sagittal No Extreme Outliers	1.689	94.592	6.901	0.003
Skeletal AP	2.043	114.400	8.977	<0.001
Skeletal AP No Extreme Outliers	2.042	112.302	8.470	<0.001
Skeletal Axial	3.036	170.019	13.983	<0.001
Skeletal Axial No Extreme Outliers	3.023	166.286	14.404	<0.001
Dental Sagittal	5.027	281.517	84.574	<0.001
Dental Sagittal No Extreme Outliers	4.675	247.793	95.704	<0.001
Dental AP	2.387	133.687	28.538	<0.001
Dental AP No Extreme Outliers	2.404	132.245	28.488	<0.001
Dental Axial	3.615	202.435	14.851	<0.001
Jaw Length, Jaw Height, IMPA	1.154	64.598	100.325	<0.001
Jaw Length, Jaw Height, IMPA No Extreme Outliers	1.151	63.283	97.295	<0.001

Figure 9. Profile Plots Indicating Landmark Directional Changes T2-T1







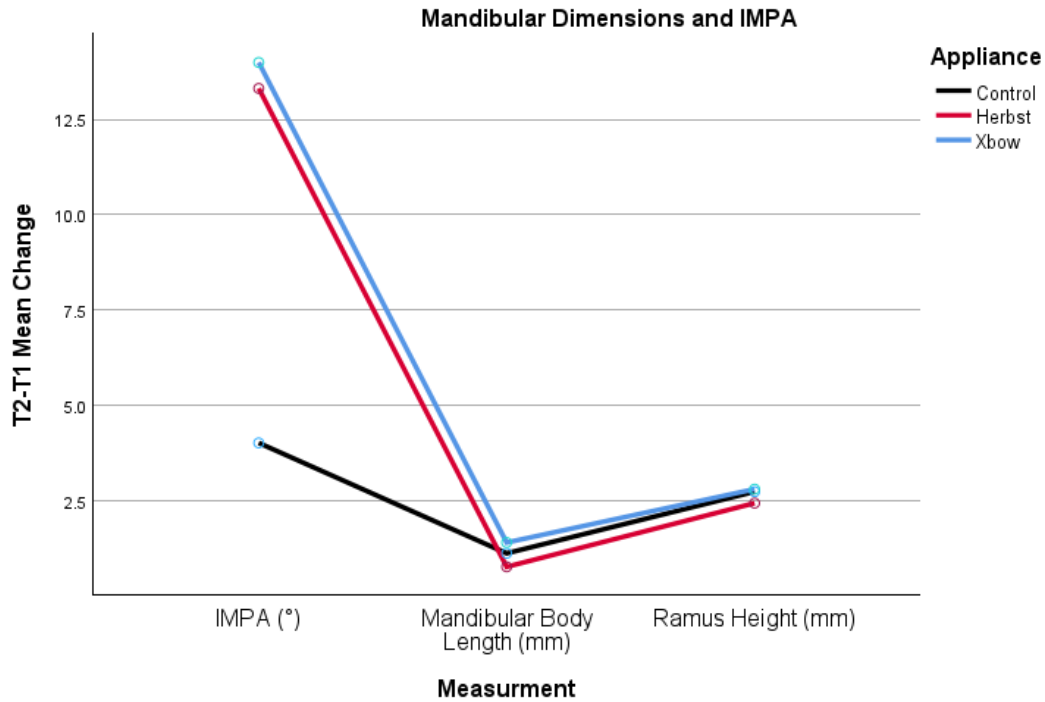


Table 21. Box's Test of Equality of Covariance Matrices One-Way Repeated ANOVA

Variables Included	Box's M	F	df1	df2	p value
Sagittal Skeletal	107.870	1.575	56	8804.414	0.004
AP Skeletal	105.460	1.540	56	8804.414	0.006
Axial Skeletal	117.795	1.295	72	8589.418	0.048
Sagittal Dental	155.680	1.711	72	8589.418	<0.001
AP Dental	172.080	1.891	72	8589.418	<0.001
Axial Dental	207.502	2.281	72	8589.418	<0.001
Mandible Dimensions & IMPA	20.071	1.541	12	14885.519	0.102

Figure 10. Scatter Matrix Skeletal Sagittal

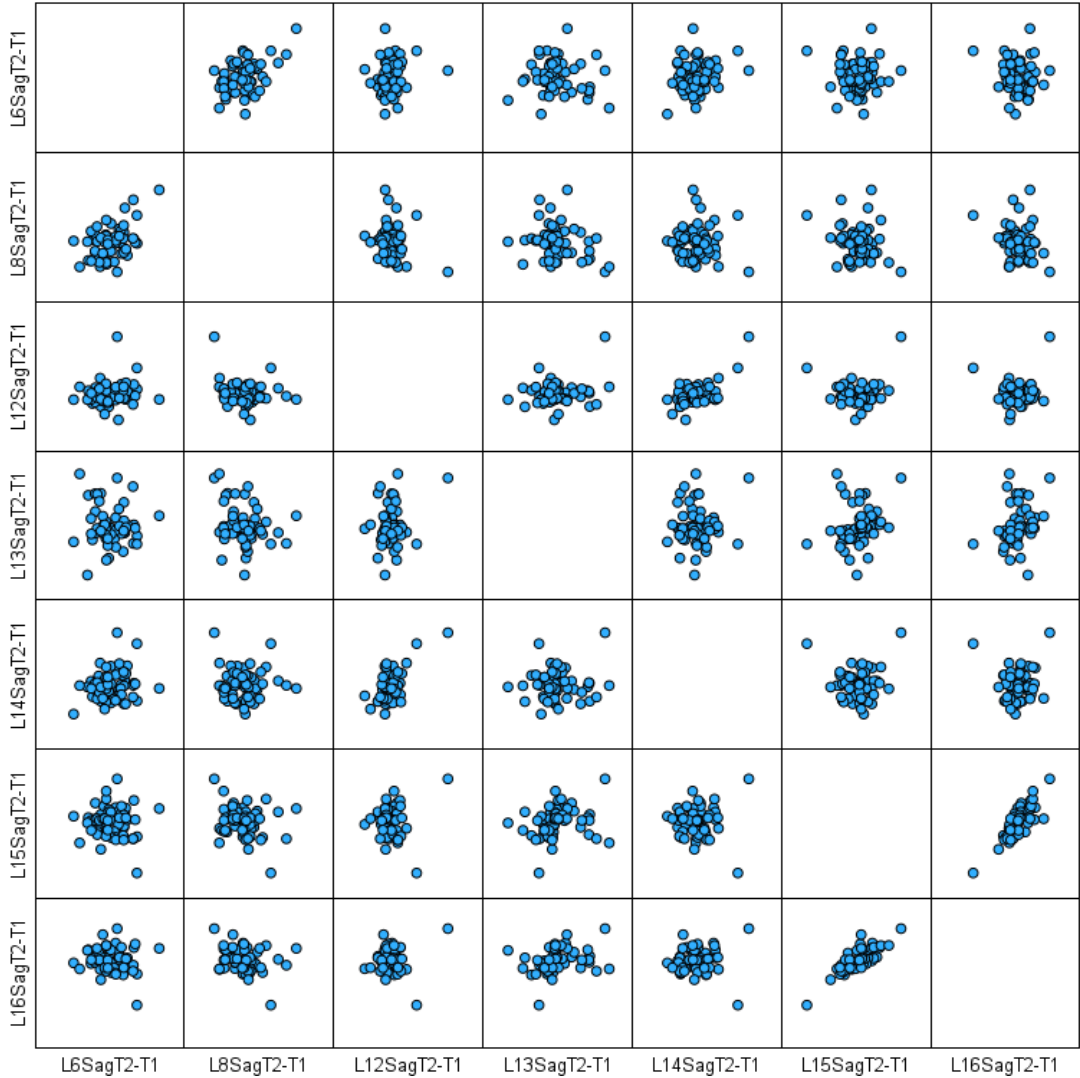


Figure 11. Boxplots for One-Way Repeated Measures ANOVA Skeletal Anteroposterior



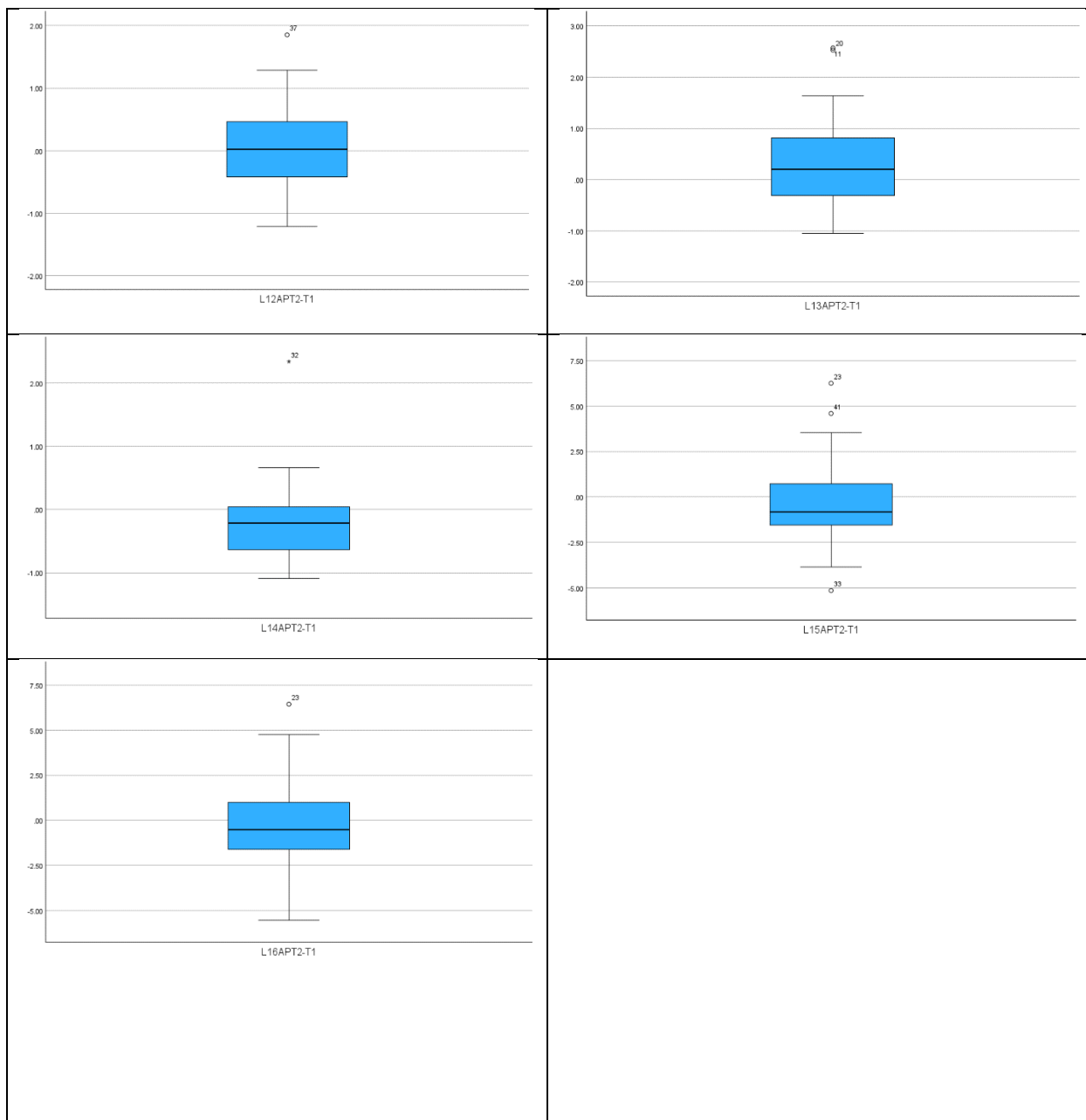


Figure 12. Scatter Matrix Skeletal Anteroposterior




Figure 13. Boxplots for One-Way Repeated Measures ANOVA Skeletal Axial



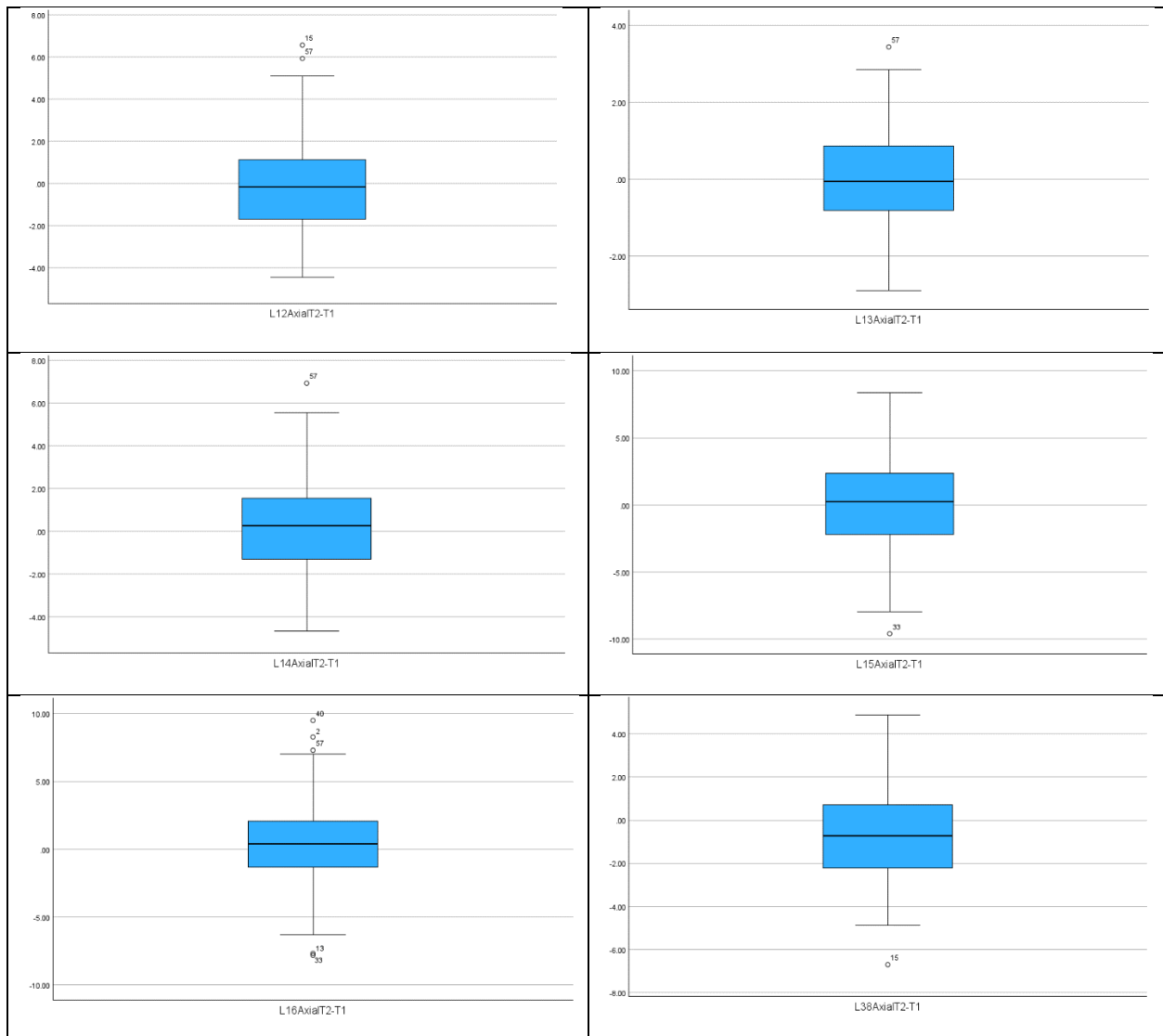


Figure 14. Scatter Matrix Skeletal Axial

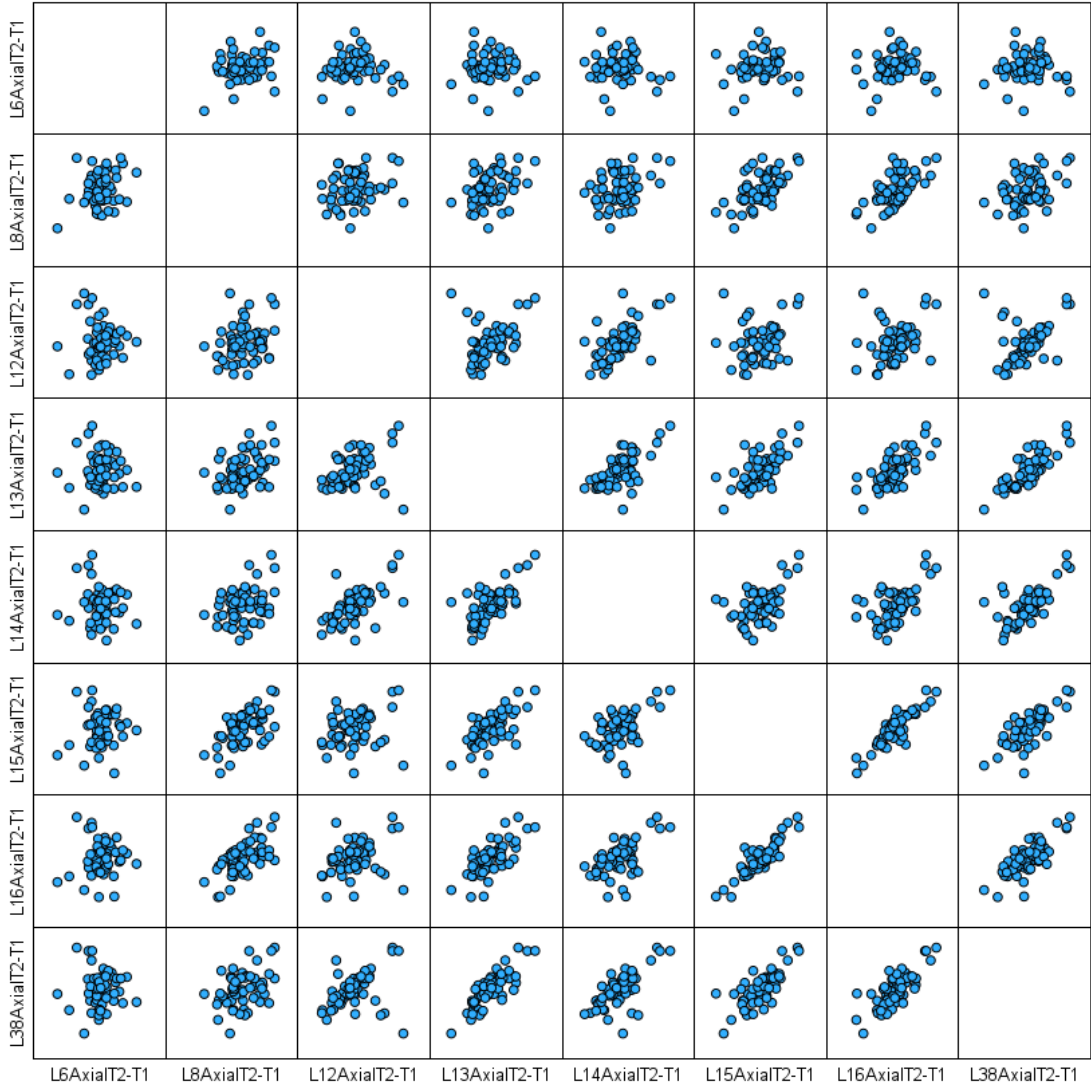


Figure 15. Boxplots for One-Way Repeated Measures ANOVA Dental Sagittal



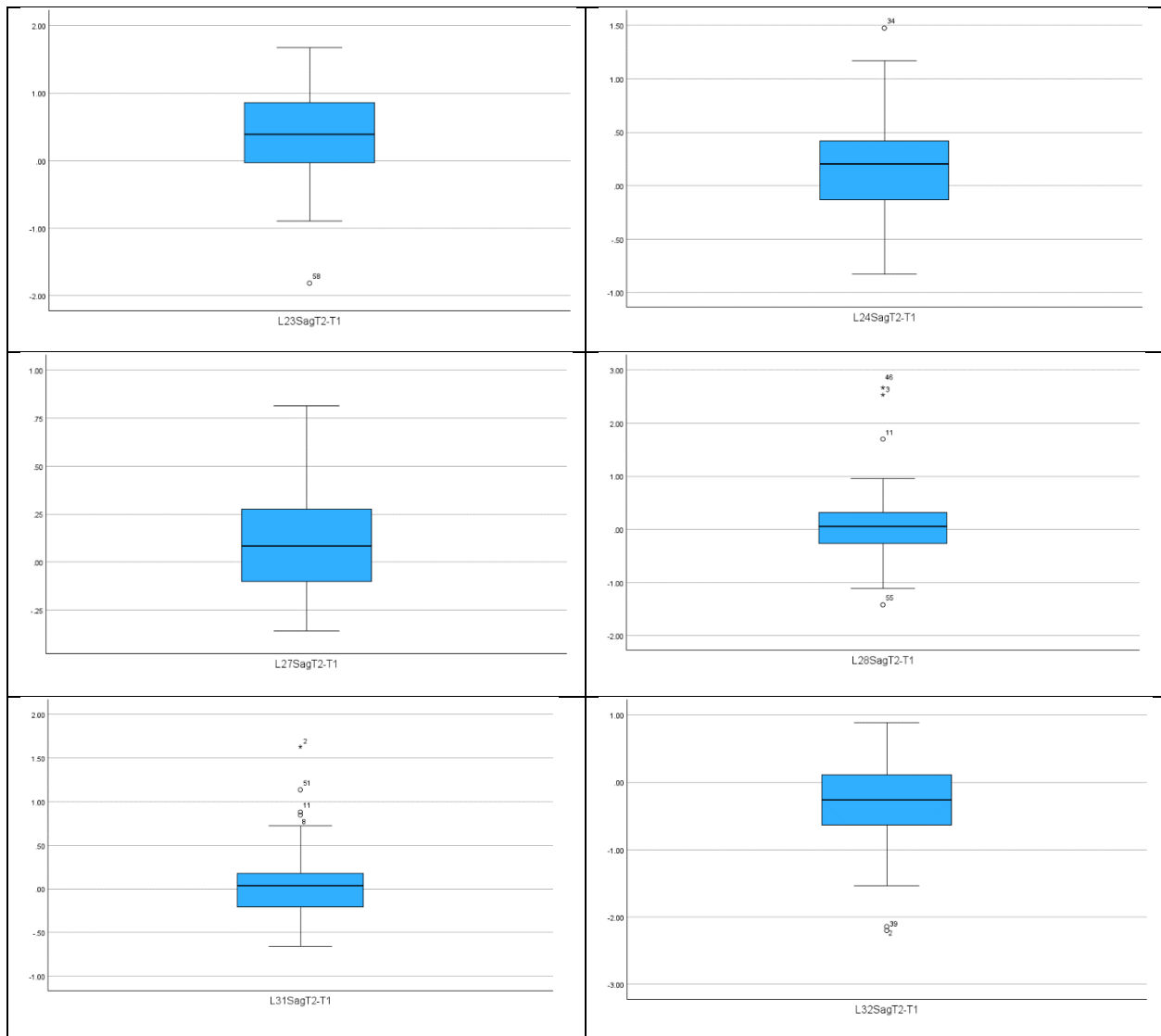


Figure 16. Scatter Matrix Dental Sagittal

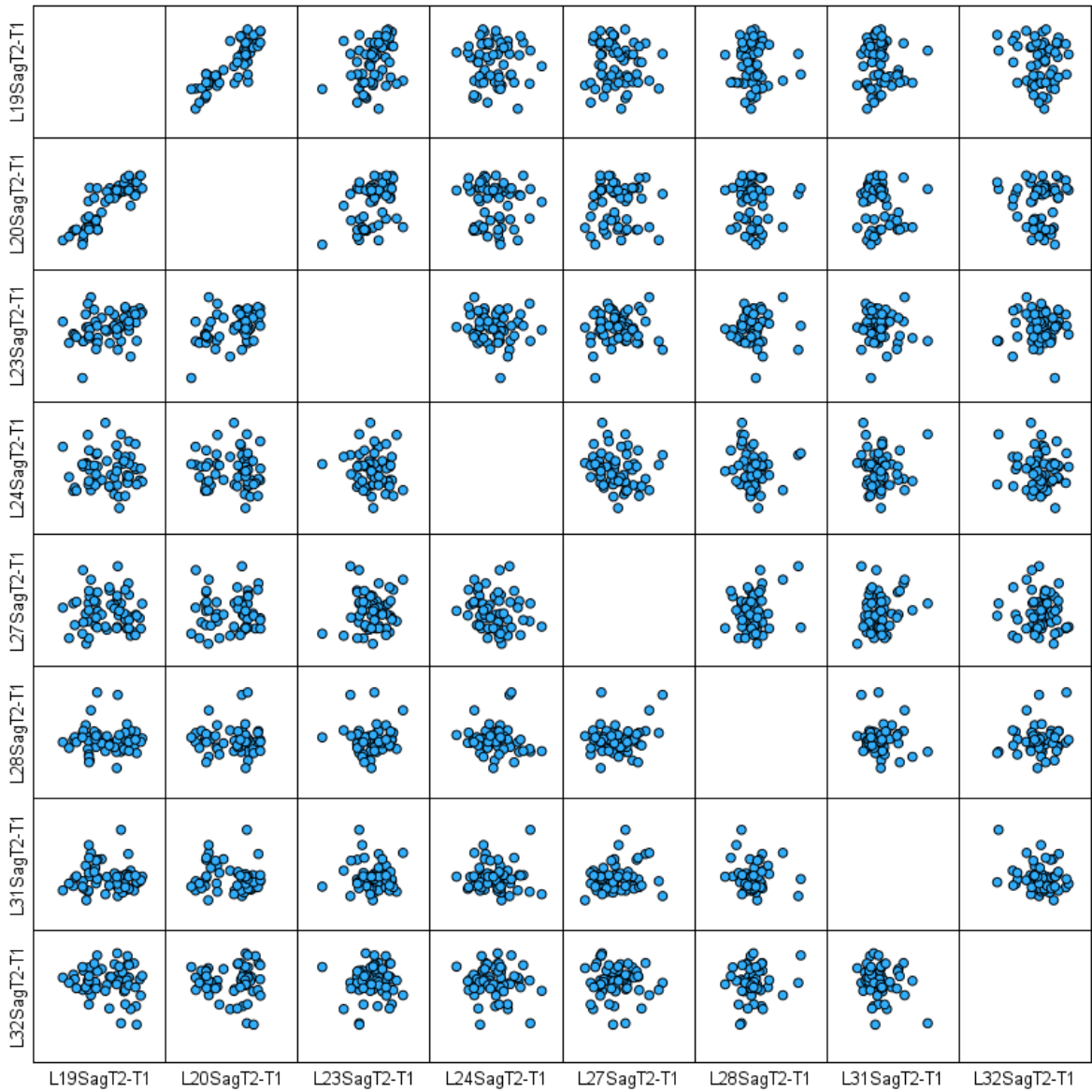



Figure 17. Boxplots for One-Way Repeated Measures ANOVA Dental Anteroposterior



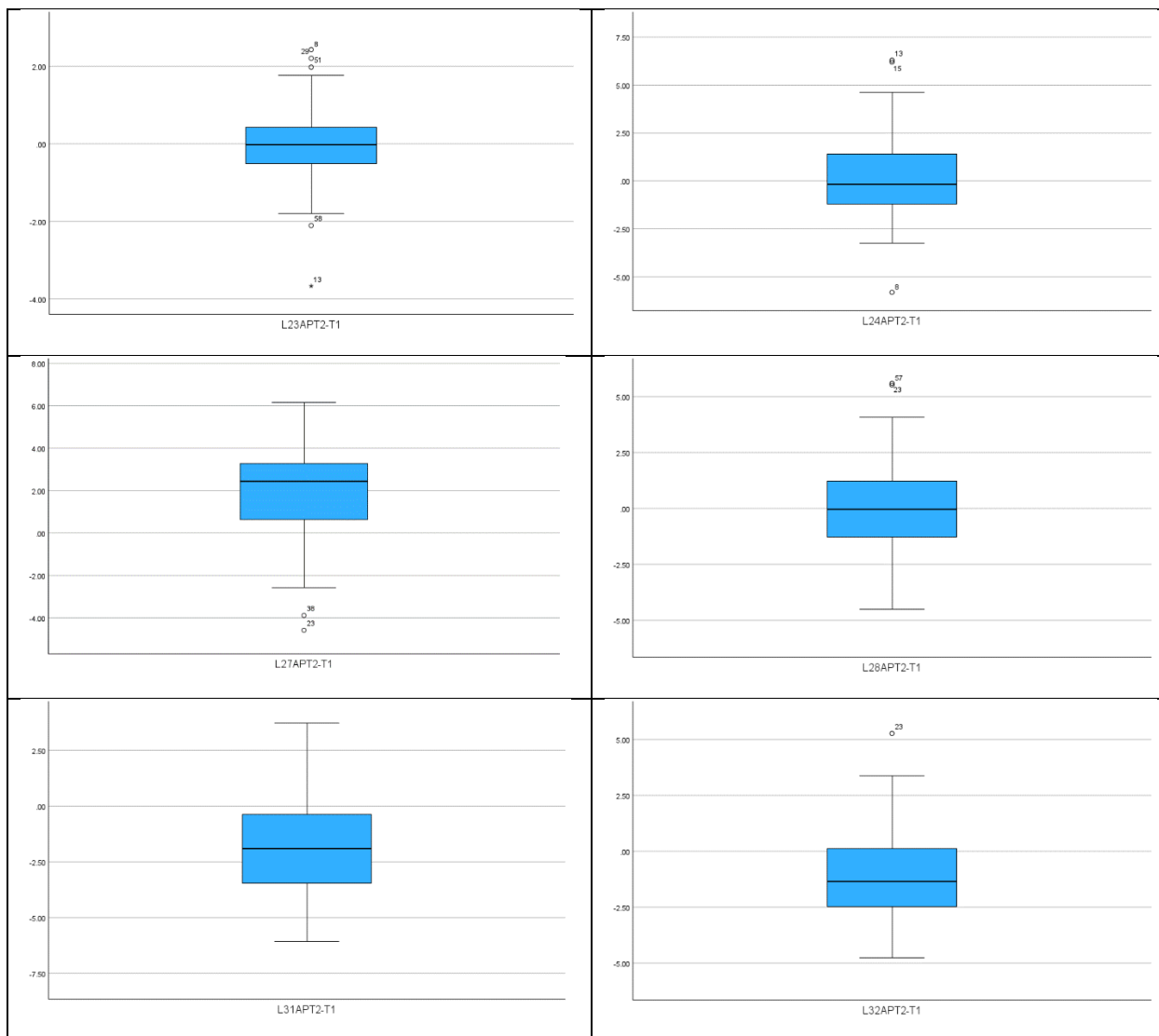


Figure 18. Scatter Matrix Dental Anteroposterior

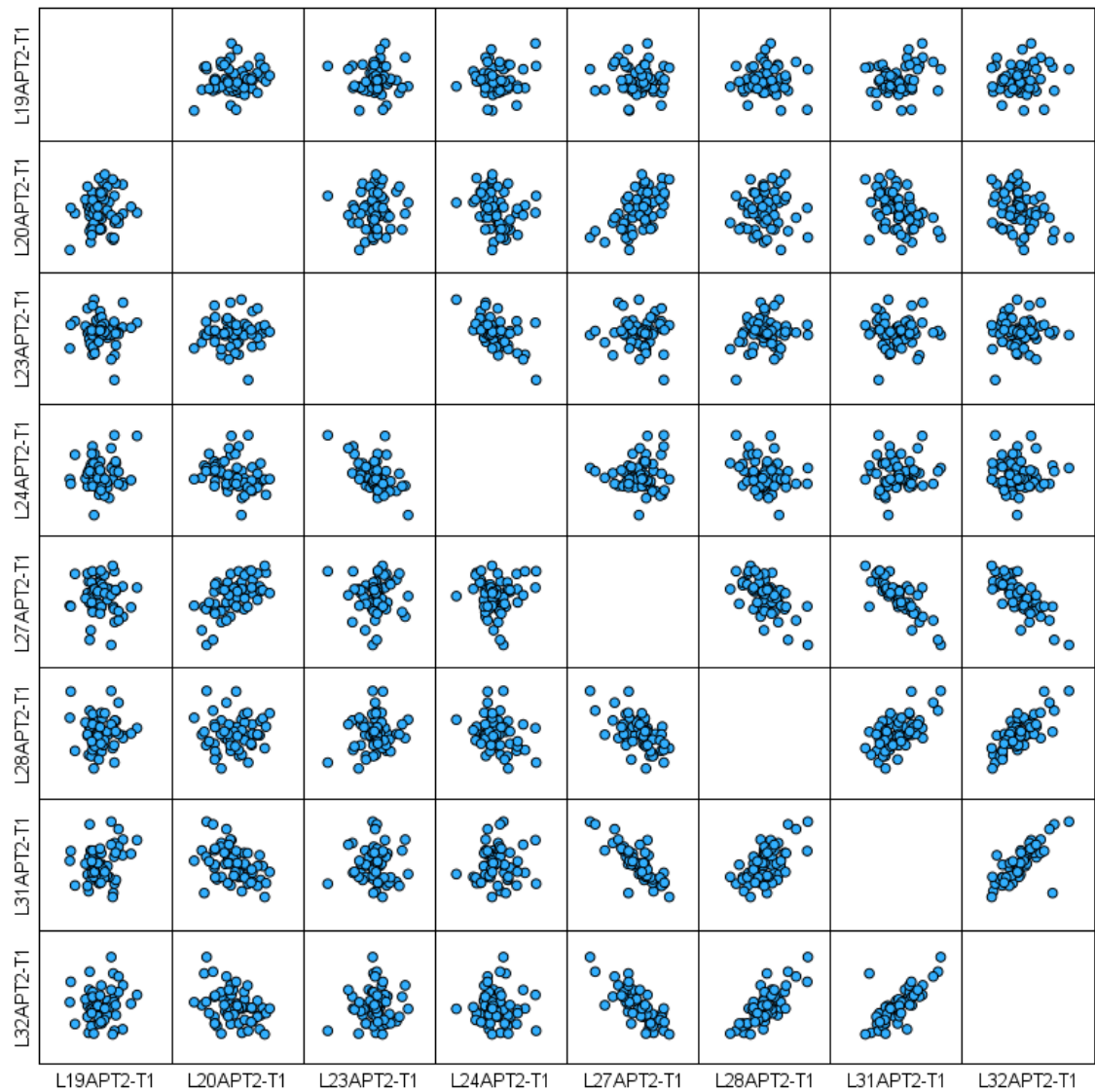



Figure 19. Boxplots for One-Way Repeated Measures ANOVA Dental Axial



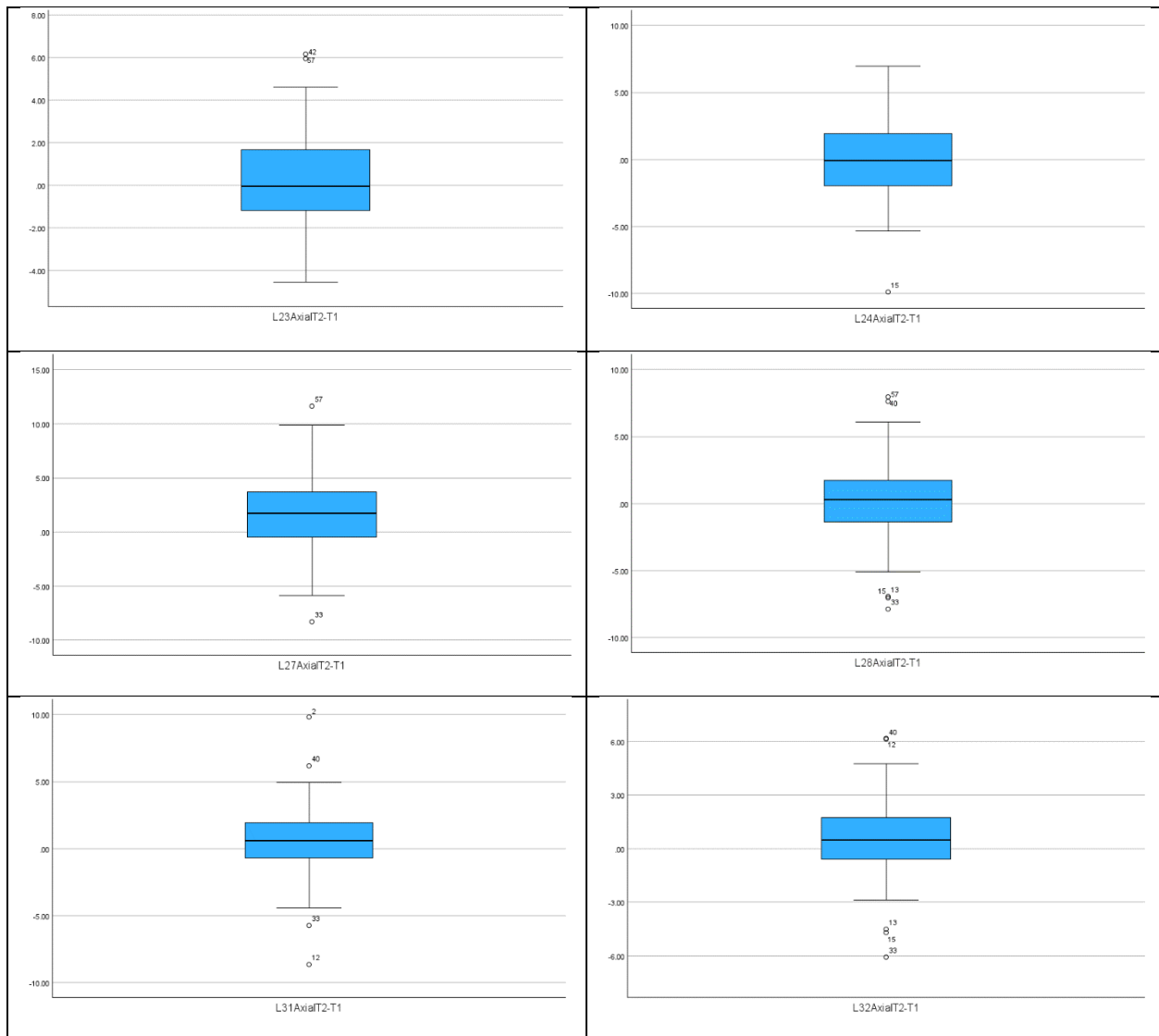


Figure 20. Scatter Matrix Dental Axial

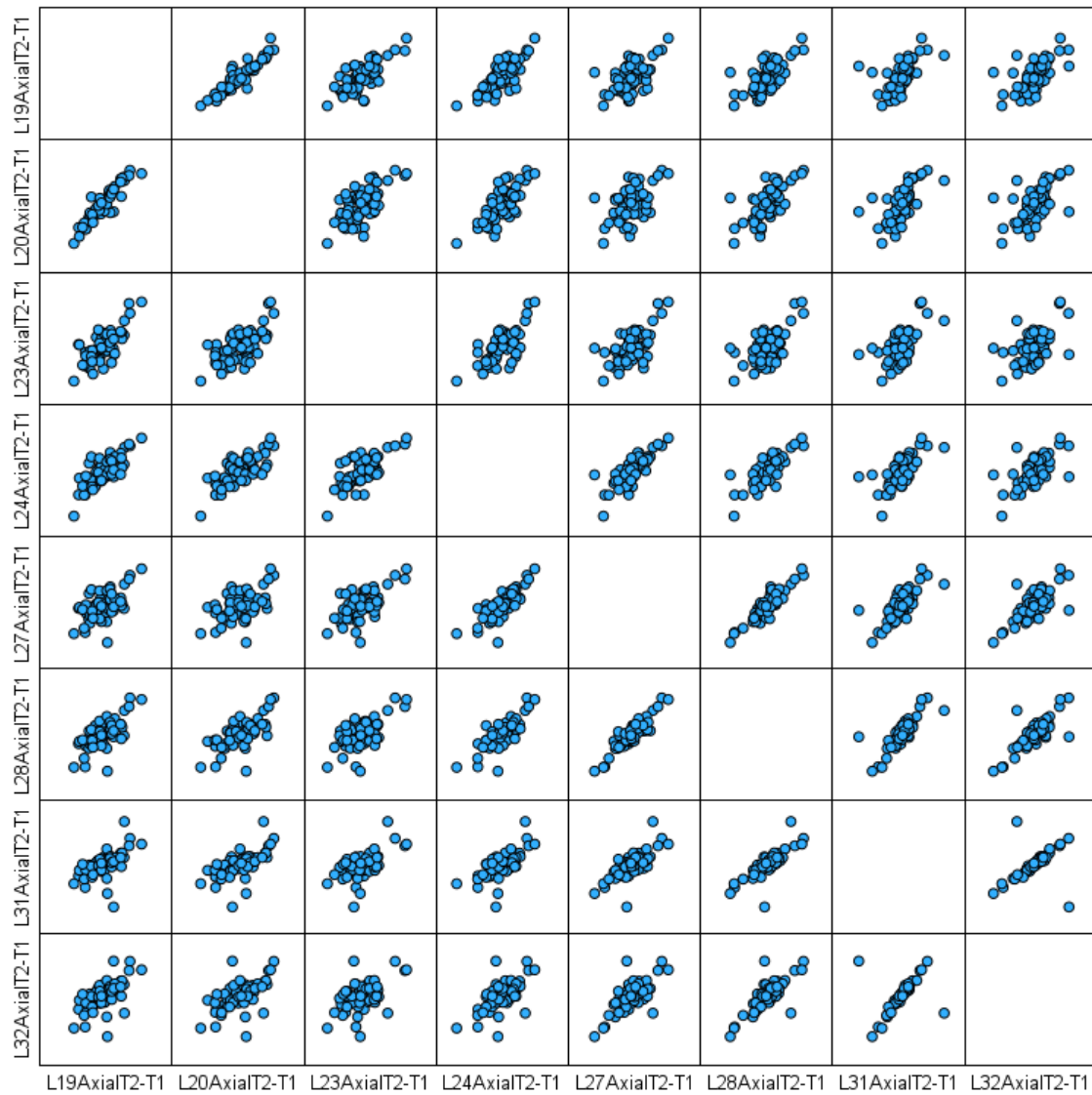


Figure 21. Boxplots for One-Way Repeated Measures ANOVA Mandible Dimensions and IMPA





Figure 22. Scatter Matrix Mandible Dimensions and IMPA

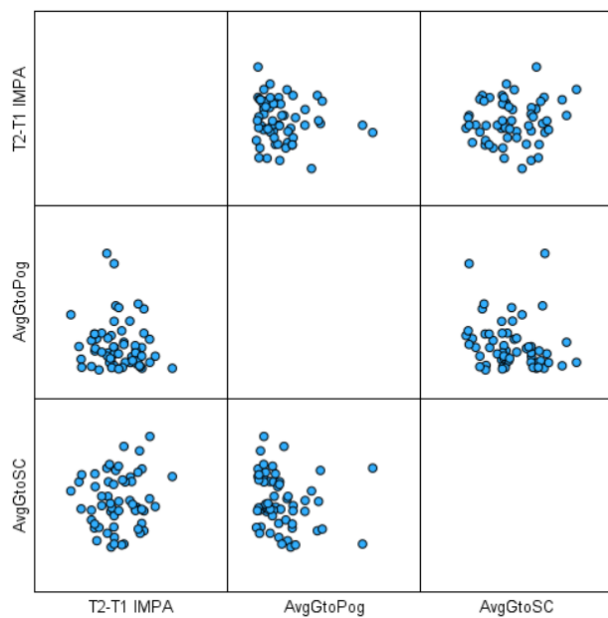


Table 22. Sample Sizes of Groups

Group	Number of Participants
Control	19
Herbst	21
Xbow	19

Table 23. Intraclass Correlation Coefficient for CBCT Landmarks

Landmark	X			Y			Z		
	ICC	95% CI	Avg SD	ICC	95% CI	Avg SD	ICC	95% CI	Avg SD
1	0.999	[0.996, 1.000]	0.132	1.000	[0.999, 1.000]	0.150	0.999	[0.998, 1.000]	0.120
2	0.996	[0.985, 0.999]	0.187	0.999	[0.997, 1.000]	0.227	1.000	[0.998, 1.000]	0.112
3	0.999	[0.996, 1.000]	0.110	1.000	[0.999, 1.000]	0.150	1.000	[0.999, 1.000]	0.088
4	0.989	[0.956, 0.997]	0.248	0.997	[0.991, 0.999]	0.307	0.997	[0.992, 0.999]	0.256
5	0.997	[0.990, 0.999]	0.164	0.996	[0.989, 0.999]	0.315	0.996	[0.990, 0.999]	0.253
6	0.966	[0.908, 0.991]	0.619	0.999	[0.997, 1.000]	0.200	0.994	[0.982, 0.998]	0.431
8	0.986	[0.961, 0.996]	0.379	0.970	[0.906, 0.992]	1.197	0.985	[0.955, 0.996]	0.796
9	0.989	[0.968, 0.997]	0.392	1.000	[0.999, 1.000]	0.161	0.998	[0.994, 0.999]	0.222
11	0.997	[0.989, 0.999]	0.219	0.988	[0.938, 0.997]	0.757	0.990	[0.962, 0.997]	0.561
12	0.993	[0.979, 0.998]	0.240	0.998	[0.995, 1.000]	0.196	0.997	[0.992, 0.999]	0.246
13	0.992	[0.977, 0.998]	0.203	0.999	[0.996, 1.000]	0.242	0.998	[0.995, 1.000]	0.225
14	0.998	[0.994, 0.999]	0.123	0.985	[0.953, 0.996]	0.603	0.999	[0.998, 1.000]	0.136

15	0.995	[0.986, 0.999]	0.198	0.992	[0.978, 0.998]	0.543	0.999	[0.997, 1.000]	0.157
16	0.995	[0.987, 0.999]	0.213	0.994	[0.980, 0.998]	0.505	0.999	[0.996, 1.000]	0.157
19	0.995	[0.985, 0.999]	0.216	0.999	[0.998, 1.000]	0.183	1.000	[0.999, 1.000]	0.118
20	0.999	[0.997, 1.000]	0.095	1.000	[0.999, 1.000]	0.091	1.000	[0.999, 1.000]	0.098
21	0.999	[0.996, 1.000]	0.097	1.000	[1.000, 1.000]	0.063	1.000	[0.999, 1.000]	0.073
22	0.995	[0.986, 0.999]	0.180	0.998	[0.994, 0.999]	0.235	0.999	[0.998, 1.000]	0.146
23	0.997	[0.993, 0.999]	0.135	0.998	[0.994, 0.999]	0.228	0.999	[0.998, 1.000]	0.153
24	0.989	[0.969, 0.997]	0.252	0.999	[0.991, 1.000]	0.201	1.000	[0.999, 1.000]	0.102
25	0.992	[0.977, 0.998]	0.218	0.999	[0.994, 1.000]	0.185	1.000	[0.999, 1.000]	0.128
26	0.996	[0.989, 0.999]	0.172	0.997	[0.985, 0.999]	0.325	0.999	[0.994, 1.000]	0.224
27	0.996	[0.987, 0.999]	0.169	0.999	[0.994, 1.000]	0.179	1.000	[0.999, 1.000]	0.100
28	0.998	[0.994, 0.999]	0.140	0.997	[0.986, 0.999]	0.296	0.999	[0.995, 1.000]	0.225
29	0.998	[0.995, 1.000]	0.139	0.996	[0.987, 0.999]	0.335	0.997	[0.990, 0.999]	0.280
30	0.996	[0.987, 0.999]	0.190	0.999	[0.995, 1.000]	0.156	1.000	[0.999, 1.000]	0.097
31	0.999	[0.997, 1.000]	0.086	1.000	[1.000, 1.000]	0.048	1.000	[1.000, 1.000]	0.062

32	0.995	[0.985, 0.999]	0.198	0.999	[0.996, 1.000]	0.240	0.995	[0.978, 0.999]	0.343
33	0.997	[0.990, 0.999]	0.213	0.999	[0.996, 1.000]	0.194	0.998	[0.988, 0.999]	0.298
34	0.999	[0.996, 1.000]	0.120	1.000	[1.000, 1.000]	0.063	1.000	[0.999, 1.000]	0.081
35	0.995	[0.981, 0.999]	0.251	0.998	[0.990, 0.999]	0.354	0.990	[0.963, 0.998]	0.509
36	0.995	[0.984, 0.999]	0.156	0.999	[0.993, 1.000]	0.274	0.993	[0.976, 0.998]	0.407
37	0.996	[0.989, 0.999]	0.163	1.000	[0.999, 1.000]	0.123	1.000	[0.999, 1.000]	0.088
38	0.994	[0.984, 0.998]	0.160	0.996	[0.988, 0.999]	0.357	0.997	[0.993, 0.999]	0.241
Landmark number with corresponding name found in Table 22 in appendix									

Table 24. Intraclass Correlation Coefficient for Lateral Cephalogram Landmarks

Landmark	X		
	ICC	95% CI	Avg SD
Gonion	0.998	[0.992, 0.999]	0.043
Menton	0.995	[0.985, 0.999]	0.046
Lower Incisor Root Tip	0.977	[0.830, 0.995]	0.100
Lower Incisor Incisal Edge	0.996	[0.990, 0.999]	0.036
	Y		
	ICC	95% CI	Avg SD
Gonion	0.994	[0.981, 0.999]	0.065
Menton	1.000	[0.998, 1.000]	0.013
Lower Incisor Root Tip	0.978	[0.900, 0.995]	0.102
Lower Incisor Incisal Edge	0.999	[0.996, 1.000]	0.023

Table 25. Labels of Each Landmark

Skeletal		Dental	
Number	Landmark	Number	Landmark
1	Right Foramen Spinosum	19	1.6 Mesiobuccal Root Apex
2	Left Foramen Spinosum	20	1.6 Pulp Chamber Center
3	ELSA	21	2.6 Pulp Chamber Center
4	Right Infraorbital Foramen	22	2.6 Mesiobuccal Root Apex
5	Left Infraorbital Foramen	23	1.1 Root Apex
6	Right Superior Condyle	24	1.1 Incisal Edge
8	Right Gonion	25	2.1 Incisal Edge
9	Left Superior Condyle	26	2.1 Root Apex
11	Left Gonion	27	3.1 Incisal Edge
12	Anterior Nasal Spine	28	3.1 Root Apex
13	Posterior Nasal Spine	29	4.1 Root Apex
14	A Point	30	4.1 Incisal Edge
15	B Point	31	4.6 Pulp Chamber Center
16	Pogonion	32	4.6 Mesial Root Apex
35	Right External Auditory Canal	33	3.6 Mesial Root Apex
36	Left External Auditory Canal	34	3.6 Pulp Chamber Center
37	Foramen Magnum		
38	Nasopalatine Foramen		